



DATE PRESENTING CLINICAL SIGNS

10/22/21

Palpable mass in neck/thyroid area; FNA performed

CYTOLOGY SUBMISSION

Thyroid region

INTERPRETED BY

L.D. McGill, DVM,
Ph.D, DACVP

OBSERVATIONS

Thyroid region: Submitted are 5 excellent videos of minimal numbers of viable cells collected from Katie. Two of the videos demonstrate degenerate protein. There are scattered keratinized cells in those collections. Two of the videos demonstrate large numbers of erythrocytes with ghost epithelial cells or other round cells. One video demonstrates viable cells interspersed with neutrophils. The cells have indistinct cytoplasmic borders with anisokaryosis and anisocytosis.

PATIENT

Katie McCourt

INTERPRETATION OF THE FINDINGS & FURTHER RECOMMENDATIONS

Thyroid region -Minimal cellularity with potential thyroid epithelial cells and extensive necrosis with secondary hemorrhage.

SPECIES

Canine

COMMENTS

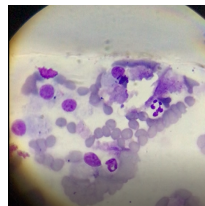
The cellularity in this collection is difficult to identify since much of it is necrotic. There is protein in 2 of the videos. The cells that are viable suggest the possibility of a proliferative process which could be thyroid or could be some other process. Hemorrhage is prominent which often occurs with aspiration of the thyroid gland region. There are changes in some of the cells that could be consistent with thyroid carcinoma but there are also changes that would suggest the possibility of a large thyroid follicular cyst or possibly a thyroglossal cyst. Excision of the mass will be required to confirm the underlying process.

BREED

Golden Retriever Mix

SEX

Female Spayed



AGE

11yrs

Image shows some of the viable cells with a neutrophil. Note the indistinct cell borders and large numbers of RBCs.

WEIGHT

59 lbs

The information and recommendations provided are based on the images presented by the referring veterinarian. No evaluation can be communicated regarding pathology that was not visible in the image/video clips provided.

HOSPITAL NAME

Rockaway Animal
Hospital

Thank you for this referral. If the clinical or image interpretation does not parallel your findings or if I can be of any further assistance please contact me.

REFERRING VET

Dr. Maniar

L.D. McGill, DVM, Ph.D., DACVP
8288 Top of the World Drive
Cottonwood Heights, UT 84121
ldmcgill.vetpath@gmail.com
cell: 801-865-1220

INVOICE NUMBER

616



DATE

10/22/21

INTERPRETED BY

L.D. McGill, DVM,
Ph.D, DACVP

PATIENT

Katie McCourt

SPECIES

Canine

BREED

Golden Retriever Mix

SEX

Female Spayed

AGE

11yrs

WEIGHT

59 lbs

HOSPITAL NAME

Rockaway Animal
Hospital

REFERRING VET

Dr. Maniar

INVOICE NUMBER

616