



DATE PRESENTING CLINICAL SIGNS

10/21/22

Vomiting more recently. Long history of pancreatitis/GI issues, has been on Budesenide for 6 years. Recently diagnosed with hyperthyroidism and started on Methimazole.

INTERPRETED BY CYTOLOGY SUBMISSION

L.D. McGill, DVM,
Ph.D, DACVP

FNA of Spleen

OBSERVATIONS

PATIENT

Emma McGarvey

Spleen: Submitted are 9 excellent videos of moderate collections of nucleated cells from the spleen in Emma. There is a background of red blood cells. The nucleated cellularity is mixed. It includes neutrophils, lymphocytes and nucleated red blood cells and scattered macrophages are identified. Malignant characteristics or sepsis are not identified.

SPECIES

Feline

INTERPRETATION OF THE FINDINGS & FURTHER RECOMMENDATIONS

Spleen - Mild chronic suppurative inflammation with some macrophages.

BREED

DSH

COMMENTS

The cellularity is not specific except for the presence of some inflammation which includes neutrophils and a very few macrophages. There is no suggestion of malignancy. The inflammatory process could be leaking from any organ in the abdominal cavity including the pancreas, liver or intestine. There is an outside possibility that this could be representative of feline infectious peritonitis. In other words, this is some type of inflammatory process which is secondarily affecting the spleen. Continued evaluation for an underlying process is encouraged.

AGE

13 years

WEIGHT

12.7 lbs

HOSPITAL NAME

Scanvet

REFERRING VET

Dr. McGarvey

INVOICE NUMBER

40630



DATE

10/21/22

INTERPRETED BY

L.D. McGill, DVM,
Ph.D, DACVP

PATIENT

Emma McGarvey

SPECIES

Feline

BREED

DSH

SEX

FS

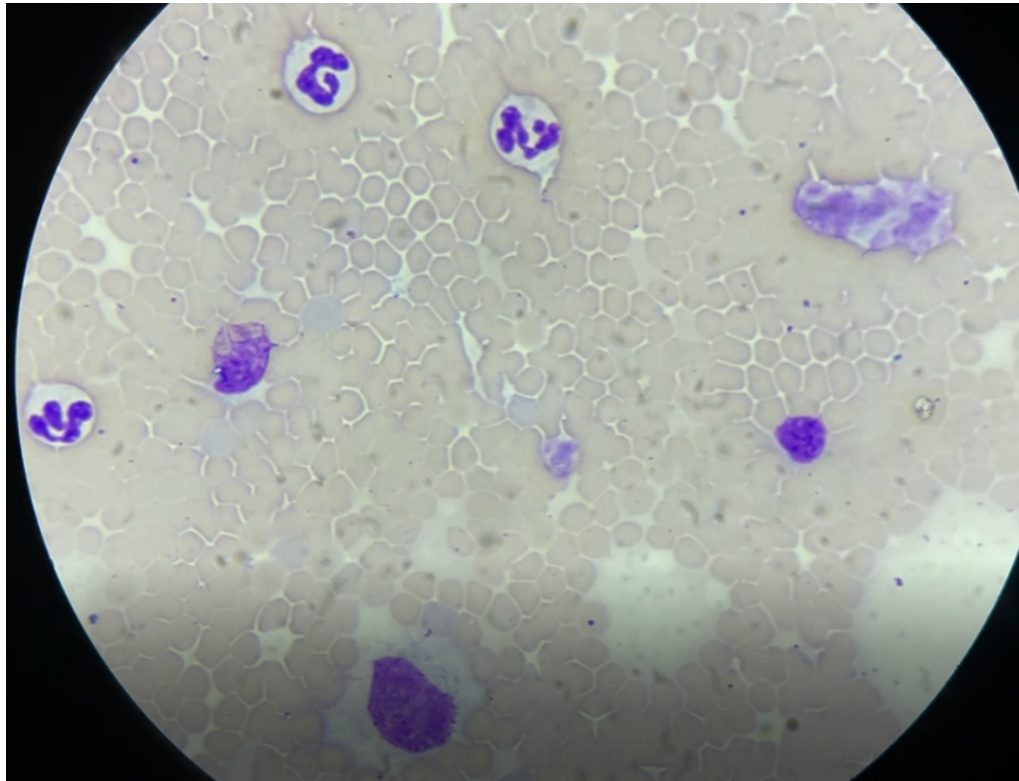


Image shows a representative collection of cells with neutrophils, lymphocytes and a macrophage collected from Emma. Note the aggregates of platelets.

AGE

13 years

The information and recommendations provided are based on the images presented by the referring veterinarian. No evaluation can be communicated regarding pathology that was not visible in the image/video clips provided.

WEIGHT

12.7 lbs

Thank you for this referral. If the clinical or image interpretation does not parallel your findings or if I can be of any further assistance, please contact me.

HOSPITAL NAME

Scanvet

L.D. McGill, DVM, Ph.D., DACVP
8288 Top of the World Drive
Cottonwood Heights, UT 84121
ldmcgill.vetpath@gmail.com
cell: 801-865-1220

REFERRING VET

Dr. McGarvey

INVOICE NUMBER

40630