



DATE PRESENTING CLINICAL SIGNS

10/2/2021

vomiting, wt loss; US showed hepatomegaly with variable lobar swelling, decreased parenchyma echogenicity, and asymmetrical contour. R/O hepatic neoplasia primary concern, non specific hepatitis, congestion, reactive hepatopathy less likely. FNA of hepatic parenchyma performed.

INTERPRETED BY

L.D. McGill, DVM, Ph.D,
DACVP

CYTOLOGY SUBMISSION

Liver

OBSERVATIONS

PATIENT

Faith Lawlor

Liver: Submitted are 4 excellent videos of cells collected from the liver in Faith. There are scattered lymphoid cells throughout scattered hepatocytes in most of the videos. There is one video that demonstrates large numbers of round cells with minimal cytoplasm. There are scattered neutrophils in the collection. The lymphoid cells have nuclei that are 4 to 6 times the size of red blood cells. Many of these cells have nucleoli. There are scattered neutrophils in the collection and a very few macrophages. Hepatocytes are not the most numerous cellularity. These lymphoid cells are most prominent particularly in the large video.

SPECIES

Canine

INTERPRETATION OF THE FINDINGS & FURTHER RECOMMENDATIONS

Liver - Large numbers of irregular lymphoid cells consistent with high-grade lymphoma.

BREED

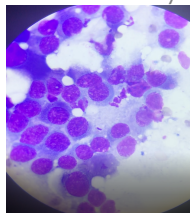
Coonhound

COMMENTS

The cellularity in this collection strongly supports a high-grade lymphoma. This lymphoma appears to be made up of large cells. Nucleoli are prominent. The 1 large excellent video includes large numbers of these cells. If chemotherapy is contemplated, immunophenotyping of the cells in this collection may be beneficial to identify cell type. This information may contribute to the prognosis. These slides may be submitted for PARR testing or biopsy and immunohistochemistry staining can be undertaken. Re-collection for flow cytometry evaluation will be required if that testing is desired. You may wish to contact the laboratory to confirm the sample required for flow cytometry. An unfavorable prognosis is warranted in my opinion.

AGE

9yr



WEIGHT

54 lbs

Image shows some of the lymphoid cells collected from the liver in Faith. Note the variation in nuclear size and some have nucleoli.

HOSPITAL NAME

Rockaway Animal Hospital

The information and recommendations provided are based on the images presented by the referring veterinarian. No evaluation can be communicated regarding pathology that was not visible in the image/video clips provided.

Thank you for this referral. If the clinical or image interpretation does not parallel your findings or if I can be of any further assistance please contact me.

REFERRING VET

Dr. Maniar

L.D. McGill, DVM, Ph.D., DACVP
8288 Top of the World Drive
Cottonwood Heights, UT 84121
ldmcgill.vetpath@gmail.com
cell: 801-865-1220

INVOICE NUMBER

605



DATE

10/2/2021

INTERPRETED BY

L.D. McGill, DVM, Ph.D,
DACVP

PATIENT

Faith Lawlor

SPECIES

Canine

BREED

Coonhound

SEX

Female Spayed

AGE

9yr

WEIGHT

54 lbs

HOSPITAL NAME

Rockaway Animal Hospital

REFERRING VET

Dr. Maniar

INVOICE NUMBER

605