

DATE PRESENTING CLINICAL SIGNS

10/19/21

The dog had accident about 2 months ago and bilateral femoral head and neck ostectomy was performed. She stayed in the hospital for a month and was eating well. The owner collected the dog last week. The dog was eating well as well at home but suddenly she stopped eating two days ago. She had one episode of vomiting. She is still active and wags her tail when approached.

INTERPRETED BY Nothing abnormal was detected on PE

L.D. McGill, DVM,
Ph.D, DACVP

Blood result was normal except that there was mild hypercalcemia, 12.1mg/dL. The abdominal X-Ray was also unremarkable. I did the blood smear and found something in the RBCs. Not sure what it is. This dog has been living in a farm and only recently been taken to home. She was given first shot of vaccination and given bravecto about 3 weeks ago

PATIENT CYTOLOGY SUBMISSION

Lucy Sara

Blood smear

OBSERVATIONS

SPECIES

Canine

Blood smear: Submitted is 1 excellent video of a blood smear. There are very few leukocytes observed. The RBCs show uniform size with scattered refractile structures and concentric staining in rings. There are a very few structures that have kind of a tear drop appearance. There are some fields with only refractile appearance and no staining. The structures are not consistent in size and shape.

INTERPRETATION OF THE FINDINGS & FURTHER RECOMMENDATIONS

BREED

Cross Breed

Blood smear - Irregular staining and refractile change with a very few structures suggesting Babesia.

COMMENTS

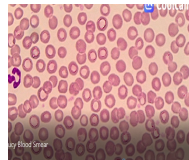SEX

Female Intact

I was unable to suggest any other hemoparasites except the potential of Babesia and I am not certain of that. I get the feeling that the RBCs sat in the tube for a bit before they were smeared. This may be the result of the RBCs drying or some other artifactual alteration. I don't think this change is the cause?? I would suggest a repeat CBC with a very fresh blood smear and see if the RBCs appear to be more appropriate. The problem is that I cannot find anything to help you with the case. You could treat for hemoparasites and see what happens but I am concerned that the actual problem is centered elsewhere.

AGE

2yr



WEIGHT

11.6

Image shows RBCs with circular artifacts in many of the RBCs. They may be hypochromic. I have seen this artifact previously.

HOSPITAL NAME

City Veterinary Clinic
Alain

The information and recommendations provided are based on the images presented by the referring veterinarian. No evaluation can be communicated regarding pathology that was not visible in the image/video clips provided.

Thank you for this referral. If the clinical or image interpretation does not parallel your findings or if I can be of any further assistance please contact me.

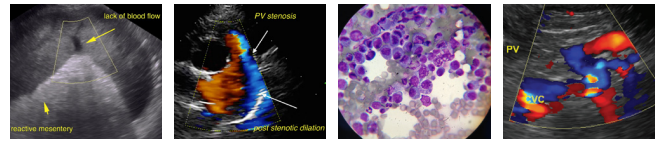
REFERRING VET

Dr. Inam ul haq

L.D. McGill, DVM, Ph.D., DACVP
8288 Top of the World Drive
Cottonwood Heights, UT 84121
ldmcgill.vetpath@gmail.com
cell: 801-865-1220

INVOICE NUMBER

615



DATE

10/19/21

INTERPRETED BY

L.D. McGill, DVM,
Ph.D, DACVP

PATIENT

Lucy Sara

SPECIES

Canine

BREED

Cross Breed

SEX

Female Intact

AGE

2yr

WEIGHT

11.6

HOSPITAL NAME

City Veterinary Clinic
Alain

REFERRING VET

Dr. Inam ul haq

INVOICE NUMBER

615