



**DATE** **PRESENTING CLINICAL SIGNS**  
10/17/22 5 mm dark black growth present left side of muzzle for unknown amount of time.

**INTERPRETED BY** **CYTOLOGY SUBMISSION**  
L.D. McGill, DVM, Ph.D, DACVP Dermal mass

**OBSERVATIONS**  
Dermal mass on the muzzle: Submitted are 20 very good images of good collections of cells from the mass on the muzzle on Babe. The cellularity consists of packets of cells many of which are vacuolated. Other cells have yellowish-brown granules in their cytoplasm. Other cells have a slight basaloid pattern. This is a characteristic proliferative process in the skin. The vacuolization suggests secretions from the epithelial cells.

**PATIENT** **INTERPRETATION OF THE FINDINGS & FURTHER RECOMMENDATIONS**  
Babe Elacqua Dermal mass on the muzzle - Characteristic of a pigmented sebaceous gland adenoma.

**SPECIES** **COMMENTS**  
Canine The cellularity is strongly suggestive of a sebaceous gland adenoma. The pigment is melanin. These growths can be pigmented, particularly when near the oral cavity. The basaloid cells could suggest the possibility of a sebaceous gland epithelioma but in general the growth appears to be benign. Excision of the mass with a follow-up biopsy is encouraged. Cytologically it is my opinion that excision, if complete, will be curative.

**BREED**  
Golden Doodle

**SEX**  
Male Neutered

**AGE**  
7/9/2014

**WEIGHT**  
105lb

**HOSPITAL NAME**  
Central Veterinary Hospital

**REFERRING VET**  
Dr. St. Sir

**INVOICE NUMBER**  
823

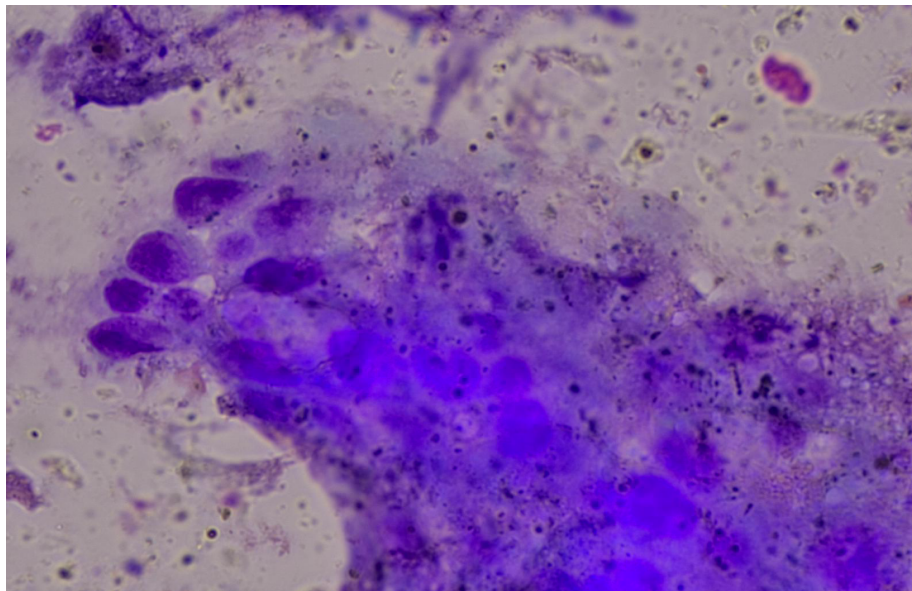


Image shows vacuolated cells with some melanin granules in the cells. The cellularity is not aggressive.

The information and recommendations provided are based on the images presented by the referring veterinarian. No evaluation can be communicated regarding pathology that was not visible in the image/video clips provided.

Thank you for this referral. If the clinical or image interpretation does not parallel your findings or if I can be of any further assistance please contact me.



**DATE**

10/17/22

**L.D. McGill, DVM, Ph.D., DACVP**

8288 Top of the World Drive  
Cottonwood Heights, UT 84121  
ldmcgill.vetpath@gmail.com  
cell: 801-865-1220

**INTERPRETED BY**

L.D. McGill, DVM, Ph.D,  
DACVP

**PATIENT**

Babe Elacqua

**SPECIES**

Canine

**BREED**

Golden Doodle

**SEX**

Male Neutered

**AGE**

7/9/2014

**WEIGHT**

105lb

**HOSPITAL NAME**

Central Veterinary  
Hospital

**REFERRING VET**

Dr. St. Sir

**INVOICE NUMBER**

823