

DATE 10/15/21
PRESENTING CLINICAL SIGNS Diagnosed in 12/2020 w/ Lymphoma; Treated w/ Modified Wisconsin Protocol and has done well until past week.

INTERPRETED BY L.D. McGill, DVM, Ph.D, DACVP
CYTOLOGY SUBMISSION U/S Guided FNA: Spleen

PATIENT Ernie Tyler
OBSERVATIONS Spleen: Submitted are 5 excellent videos of very good collections of cells from the spleen in Ernie. The cellularity is rather uniform. 95% or more of the cells in these smears are round cells with minimal to slight cytoplasm which is bluish gray. The cytoplasm appears to be very lightly granular but this is not atypical. The nuclei are 2 to 4 times the size of red blood cells and many have prominent nucleoli. This is a very consistent cellularity which is common with lymphoid neoplasia. There are very few neutrophils present. Mitotic figures are observed.

SPECIES Canine
INTERPRETATION OF THE FINDINGS & FURTHER RECOMMENDATIONS Spleen - Consistent with high grade lymphoma

BREED Beagle
COMMENTS

SEX Male Neutered
The cellularity is strongly suggestive of a high-grade lymphoma in this collection from Ernie. These are excellent videos although the image is slightly off-center. You can probably adjust that with your phone. The cellularity is strongly supportive of a highly grade lymphoma. If chemotherapy is contemplated, immunophenotyping of the cells in this collection may be beneficial to identify cell type. This information may contribute to the prognosis. These slides may be submitted for PARR testing or biopsy and immunohistochemistry staining can be undertaken. Re-collection for flow cytometry evaluation will be required if that testing is desired. You may wish to contact the laboratory to confirm the sample required for flow cytometry. I suspect that the liver is also involved. There are forms of lymphoma that affect only the liver and spleen. In my opinion an unfavorable prognosis is warranted.

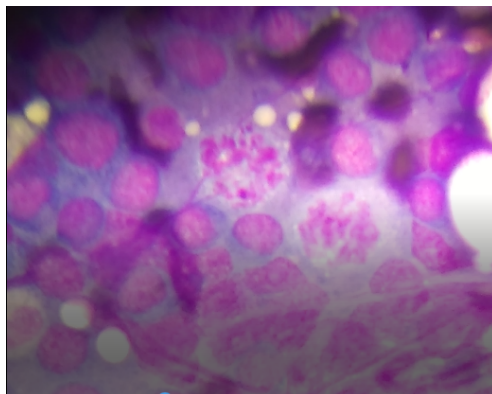
AGE 9yrs
Image shows the lymphoid cells with large nuclei and prominent nucleoli with 2 mitotic figures collected from Ernie. The cells have a lymphoid appearance.

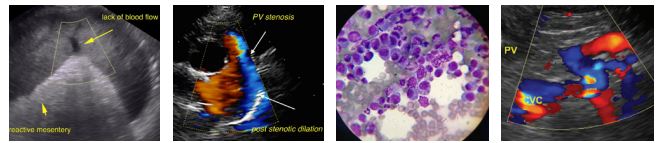
WEIGHT 62lbs

HOSPITAL NAME Franklin Animal Clinic

REFERRING VET Dr. Doverspike

INVOICE NUMBER 9082





DATE 10/15/21 The information and recommendations provided are based on the images presented by the referring veterinarian. No evaluation can be communicated regarding pathology that was not visible in the image/video clips provided.

INTERPRETED BY L.D. McGill, DVM, Ph.D., DACVP Thank you for this referral. If the clinical or image interpretation does not parallel your findings or if I can be of any further assistance please contact me.

L.D. McGill, DVM,
Ph.D., DACVP

L.D. McGill, DVM, Ph.D., DACVP
8288 Top of the World Drive
Cottonwood Heights, UT 84121
ldmcgill.vetpath@gmail.com
cell: 801-865-1220

PATIENT
Ernie Tyler

SPECIES
Canine

BREED
Beagle

SEX
Male Neutered

AGE
9yrs

WEIGHT
62lbs

HOSPITAL NAME
Franklin Animal Clinic

REFERRING VET
Dr. Doverspike

INVOICE NUMBER
9082