



DATE PRESENTING CLINICAL SIGNS

10/14/22

Large cutaneous mobile ulcerated mass (25mm) at the base of the right ear.

INTERPRETED BY CYTOLOGY SUBMISSION

L.D. McGill, DVM,
Ph.D, DACVP

FNA of Subcutaneous mass

PATIENT OBSERVATIONS

Ranger Audette

Subcutaneous mass: Submitted are 4 excellent videos of excellent collections of cells from the subcutaneous mass on Ranger. The cellularity is mixed with large numbers of eosinophils and large numbers of round cells many of which have purple to metachromatic granules. Many of the cells with purple granules are minimally granulated. There are interspersed cells that have a lymphoid pattern and appear to be atypical lymphoid cells. This causes concern about a complex type of neoplastic process.

SPECIES

Canine

BREED

German Shepherd

INTERPRETATION OF THE FINDINGS & FURTHER RECOMMENDATIONS

Subcutaneous mass - Round cell tumor consistent with high-grade mast cell tumor and possible high-grade lymphoma.

SEX

Male Neutered

AGE

11y

WEIGHT

53lbs

COMMENTS

This is definitely a neoplastic round cell tumor. Due to the eosinophils and the granulated cells, a high-grade mast cell tumor appears to be a major process. My concern is the presence of what appear to be large atypical lymphoid cells as well. In these collections, there appears to be a combination of high-grade mast cell tumor and high-grade lymphoma in the same collection. It is possible that many of the cells that have a lymphoid pattern could be degranulated mast cells, but they are certainly somewhat unusual in their pattern in this collection. Wide excision of the mass and submission for biopsy to confirm the process is encouraged. I'm very concerned about this mass and the potential it has for Ranger. With the irregular cells, an unfavorable prognosis is warranted in my opinion. Besides evaluating this mass, aspirates of liver, spleen and regional lymph node should be considered to assist in staging this mass.

HOSPITAL NAME

Rotterdam Veterinary
Hospital

REFERRING VET

Dr. Anna St.Sir

INVOICE NUMBER

40625



DATE

10/14/22

INTERPRETED BY

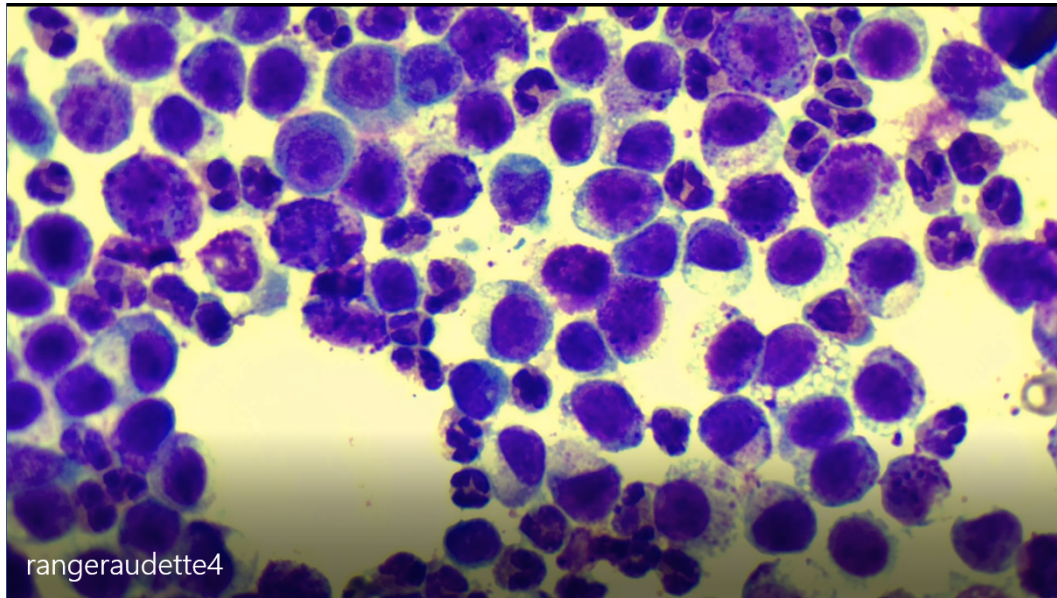
L.D. McGill, DVM,
Ph.D., DACVP

PATIENT

Ranger Audette

SPECIES

Canine



BREED

German Shepherd

SEX

Male Neutered

AGE

11y

WEIGHT

53lbs

HOSPITAL NAME

Rotterdam Veterinary
Hospital

REFERRING VET

Dr. Anna St.Sir

INVOICE NUMBER

40625

Image shows the representative cells collected from the subcutaneous mass on Ranger. Note the eosinophils, granulated cells and some cells suggest large lymphoid cells.

The information and recommendations provided are based on the images presented by the referring veterinarian. No evaluation can be communicated regarding pathology that was not visible in the image/video clips provided.

Thank you for this referral. If the clinical or image interpretation does not parallel your findings or if I can be of any further assistance, please contact me.

L.D. McGill, DVM, Ph.D., DACVP
8288 Top of the World Drive
Cottonwood Heights, UT 84121
ldmcgill.vetpath@gmail.com
cell: 801-865-1220