



DATE PRESENTING CLINICAL SIGNS

10/11/22

Patient presented 10/8/22 for rapidly growing mass on right hind leg. Mass on lateral aspect of stifle 8 cm x 7 cm. Mass firm and warm. R/o sarcoma, nerve sheath tumor.

INTERPRETED BY CYTOLOGY SUBMISSION

L.D. McGill, DVM,
Ph.D, DACVP

FNA of Dermal

OBSERVATIONS

PATIENT

Chongo Carvajal

Stifle region mass: Submitted are a large number of excellent images of moderate to excellent collections of cells from the stifle region mass on Chongo. The majority of the cells are large, rounded cells with prominent cytoplasm. The cells have slightly vacuolated cytoplasm. Interspersed are scattered neutrophils and lymphocytes. There are many fields that are filled with the larger round cells. They are slightly pleomorphic with slight anisokaryosis. Many of the cells have slightly granular cytoplasm.

SPECIES

Canine

INTERPRETATION OF THE FINDINGS & FURTHER RECOMMENDATIONS

Stifle region mass - Large round cell proliferation suggesting granulomatous inflammation or possible histiocytic synovial sarcoma.

BREED

lab mix

COMMENTS

The cellularity has a histiocytic or macrophage pattern. There are some fields that suggest the possibility of chronic inflammation such as a granulomatous inflammatory process. That type of reaction certainly could have increased temperature. There are many other fields however that suggest the possibility of a histiocytic proliferative process such as a histiocytic synovial sarcoma. If the joint is involved, then this type of process should be considered strongly. A follow-up biopsy will be required to confirm the diagnosis. It is not a spindle cell tumor in the collection submitted. A guarded prognosis is warranted particularly if this appears to be involving the synovium.

AGE

12y

WEIGHT

77 lb

HOSPITAL NAME

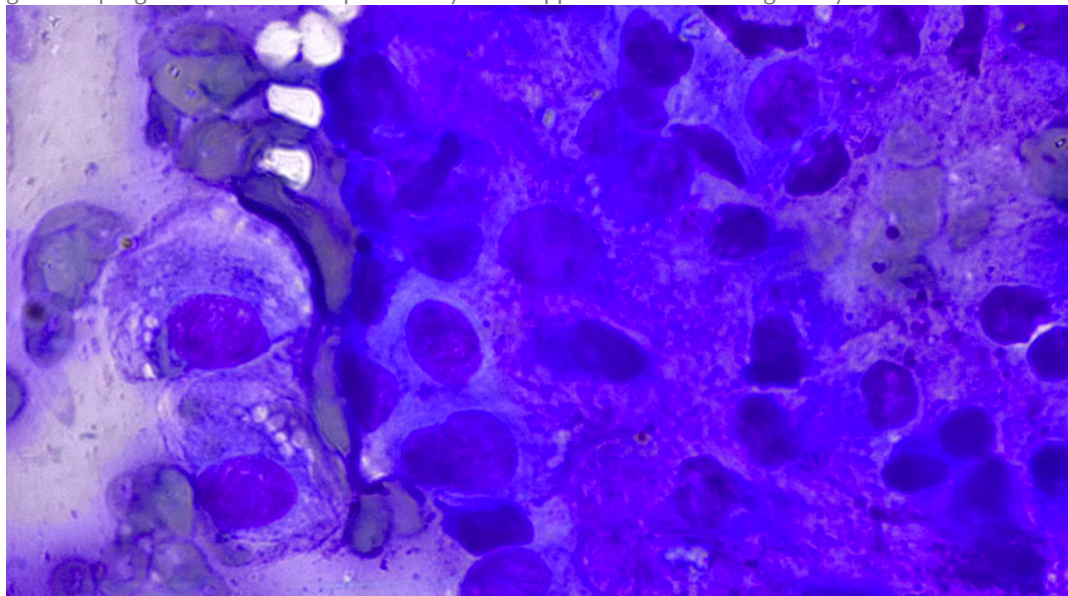
Central Veterinary
Hospital

REFERRING VET

Dr. Cheryl Goeldner

INVOICE NUMBER

40620



This image shows a large clump of cells collected from the stifle area on Chongo. There is anisocytosis and anisokaryosis. Note the well represented histiocytic cells to the left.



DATE 10/11/22 The information and recommendations provided are based on the images presented by the referring veterinarian. No evaluation can be communicated regarding pathology that was not visible in the image/video clips provided.

INTERPRETED BY L.D. McGill, DVM, Ph.D., DACVP Thank you for this referral. If the clinical or image interpretation does not parallel your findings or if I can be of any further assistance, please contact me.

L.D. McGill, DVM,
Ph.D., DACVP

L.D. McGill, DVM, Ph.D., DACVP
8288 Top of the World Drive
Cottonwood Heights, UT 84121
ldmcgill.vetpath@gmail.com
cell: 801-865-1220

PATIENT
Chongo Carvajal

SPECIES

Canine

BREED

lab mix

SEX

Male Neutered

AGE

12y

WEIGHT

77 lb

HOSPITAL NAME

Central Veterinary
Hospital

REFERRING VET

Dr. Cheryl Goeldner

INVOICE NUMBER

40620