



**DATE PRESENTING CLINICAL SIGNS**

10/10/22

Enlarged lymph node in cervical region left side

**INTERPRETED BY CYTOLOGY SUBMISSION**

L.D. McGill, DVM,  
Ph.D, DACVP

FNA of Lymph Node

**PATIENT OBSERVATIONS**

Walter Waffle

Lymph node: Submitted are 12 images of cells collected from the lymph node in Walter. The cellularity consists of large numbers of small lymphocytes with nuclei that are the same size as red blood cells. There are larger lymphoid cells, but they are fewer in numbers. There are scattered neutrophils. There are scattered degenerate cells in the collection. The number of small cells in this collection is 70 to 80%.

**SPECIES**

Canine

**INTERPRETATION OF THE FINDINGS & FURTHER RECOMMENDATIONS**

**BREED**

Springer

Lymph node - Characteristic of reactive lymphoid tissue with mild suppuratoidve inflammation.

**SEX**

Male Neutered

The cellularity in this lymph node is characteristic of reactive lymph tissue. The majority of the cells are small mature lymphocytes. There is some mild inflammation. This lymph node is reactive and could also be a reactive lymph node of the young dog. The lymph node should be continually monitored but there is no suggestion of neoplasia at this time. I suspect that this is a reaction to some type of inflammatory response in the head or neck region. This cellularity is definitely benign.

**AGE**

1y

**WEIGHT**

44lb

**HOSPITAL NAME**

Torch Lake Veterinary  
Clinic

**REFERRING VET**

Dr. Waffle

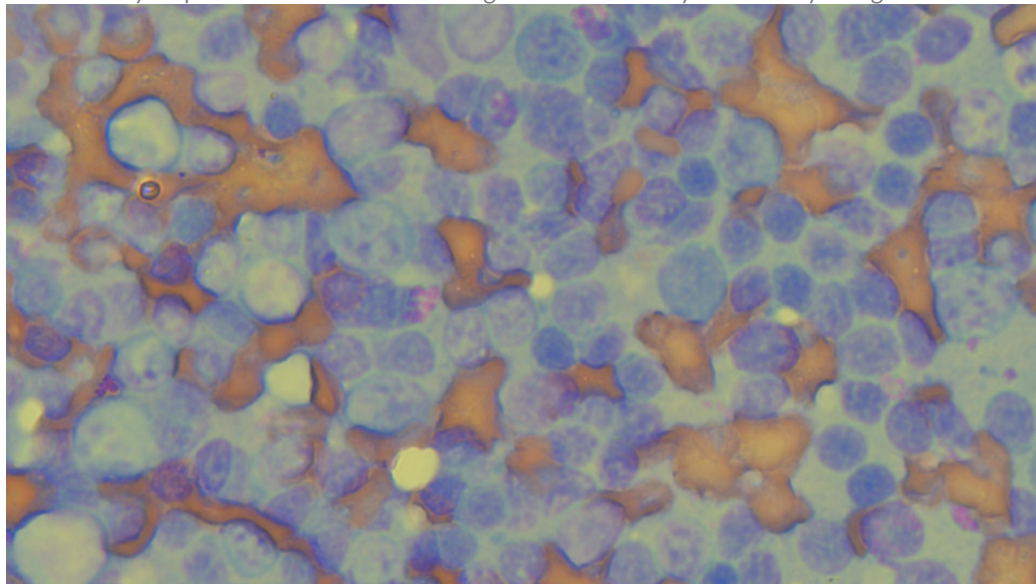


Image shows a good collection of lymphocytes from the lymph node in Walter. Note the high percentage of small lymphocytes compared to the few larger cells in this collection.

**INVOICE NUMBER**

40617



**DATE**

10/10/22

The information and recommendations provided are based on the images presented by the referring veterinarian. No evaluation can be communicated regarding pathology that was not visible in the image/video clips provided.

**INTERPRETED BY**

L.D. McGill, DVM,  
Ph.D., DACVP

Thank you for this referral. If the clinical or image interpretation does not parallel your findings or if I can be of any further assistance, please contact me.

**PATIENT**

Walter Waffle

**L.D. McGill, DVM, Ph.D., DACVP**  
8288 Top of the World Drive  
Cottonwood Heights, UT 84121  
ldmcgill.vetpath@gmail.com  
cell: 801-865-1220

**SPECIES**

Canine

**BREED**

Springer

**SEX**

Male Neutered

**AGE**

1y

**WEIGHT**

44lb

**HOSPITAL NAME**

Torch Lake Veterinary  
Clinic

**REFERRING VET**

Dr. Waffle

**INVOICE NUMBER**

40617