



**DATE PRESENTING CLINICAL SIGNS**

10/10/22

Cat reported with having a Lump/mass present at the base of tail with multiple fistulas, having serous discharges.

Cat had an abscess around 6 months ago, and was drained and cleaned, followed by surgical closure. Owner have observed that a mass is present on the same region again a week ago, and now the mass is firm and immovable. antibiotics (amoxiclav) was administered for a week. after the antibiotic course, the mass is little reduced in size but not that significant, so FNA was performed, and file is attached with the case.

**INTERPRETED BY**

L.D. McGill, DVM,  
Ph.D, DACVP

**PATIENT CYTOLOGY SUBMISSION**

FNA of Dermal- Subcutaneous aspirate

Nefertiti Sylvian

**OBSERVATIONS**

**SPECIES**

Feline

Subcutaneous aspirate: Submitted is a video of several images of cells collected from the subcutaneous site near the pale head region on Nefertiti. The cellularity consists of red blood cells interspersed with neutrophils, scattered macrophages, and rare mononuclear cells. The neutrophils are degenerate in many sites and there appears to be a background of some bacteria. There are no cells with criteria of malignancy.

**BREED**

Domestic Short Hair

**INTERPRETATION OF THE FINDINGS & FURTHER RECOMMENDATIONS**

Subcutaneous aspirate - Severe chronic suppurative inflammation with hemorrhage.

**SEX**

Female Spayed

**COMMENTS**

The cellularity supports a severe inflammatory process and bacterial infection. Continued treatment with antibacterial products is encouraged. Bacterial culture may be beneficial. I would be concerned about the potential of methicillin-resistant bacteria. A guarded prognosis is warranted but continued treatment for bacterial infection is encouraged. Some anti-inflammatory agents may also be required. A guarded prognosis is warranted since we are not certain as to how Nefertiti will respond to therapy.

**AGE**

4yr

**WEIGHT**

5.1kg

**HOSPITAL NAME**

Pawsitive Veterinary  
Clinic Dubai Silicon  
Oasis

**REFERRING VET**

Dr. Iftikhar

**INVOICE NUMBER**

40615



**DATE**

10/10/22

**INTERPRETED BY**

L.D. McGill, DVM,  
Ph.D, DACVP

**PATIENT**

Nefertiti Sylvian

**SPECIES**

Feline

**BREED**

Domestic Short Hair

**SEX**

Female Spayed

**AGE**

4yr

**WEIGHT**

5.1kg

**HOSPITAL NAME**

Pawsitive Veterinary  
Clinic Dubai Silicon  
Oasis

**REFERRING VET**

Dr. Iftikhar

**INVOICE NUMBER**

40615

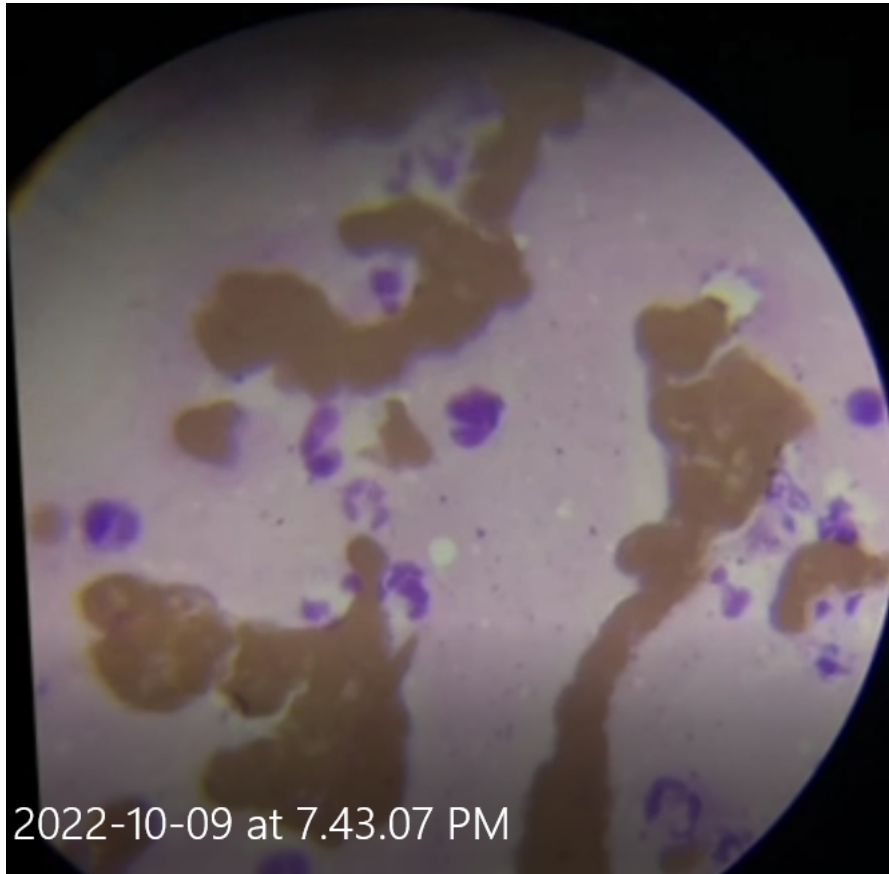


Image shows a group of neutrophils, many of which are degenerate collected from Nefertiti. There may be bacteria in the background with RBCs.

The information and recommendations provided are based on the images presented by the referring veterinarian. No evaluation can be communicated regarding pathology that was not visible in the image/video clips provided.

Thank you for this referral. If the clinical or image interpretation does not parallel your findings or if I can be of any further assistance, please contact me.

L.D. McGill, DVM, Ph.D., DACVP  
8288 Top of the World Drive  
Cottonwood Heights, UT 84121  
ldmcgill.vetpath@gmail.com  
cell: 801-865-1220