



DATE PRESENTING CLINICAL SIGNS

1/7/23

Patient presented for annual exam 1/7/23 with new lump in right groin area. Firm, irregular, subcutaneous. Seems sensitive to touch per owner.

INTERPRETED BY

CYTOLOGY SUBMISSION

Right groin lump

L.D. McGill, DVM,
Ph.D, DACVP

OBSERVATIONS

Right groin lump: Submitted are 2 excellent videos of excellent collections of cells from the right groin lump on Brandy. The cellularity consists of large numbers of lymphoid cells interspersed with neutrophils and eosinophils. The lymphoid cells are mainly small lymphocytes with some intermediate lymphocytes and scattered reactive lymphoid cells with large nuclei and prominent nucleoli. The lymphoid cells are regular. The large lymphoid cells are approximately 30% of the cellularity. Eosinophils and neutrophils are readily identified.

PATIENT

Brandy Hynes

INTERPRETATION OF THE FINDINGS & FURTHER RECOMMENDATIONS

SPECIES

Right groin lump - Chronic pyogranulomatous and eosinophilic lymphadenitis with markedly reactive lymphoid tissue.

Canine

COMMENTS

The cellularity at this time is most characteristic of a markedly reactive lymph node with inflammation draining to that node. This inflammation includes eosinophils and neutrophils. The number of irregular lymphoid cells is less than 50% and thus it is more characteristic of a reactive lymph node than neoplasia. I did consider lymphoma but the cellularity does not suggest that possibility in these smears. If other lymph nodes become involved following treatment for inflammation, then further evaluation for lymphoma would be encouraged. With the slides we have, I expect a favorable prognosis unless other lymph nodes become involved in the near future.

BREED

Lab Retriever

SEX

Female Spayed

AGE

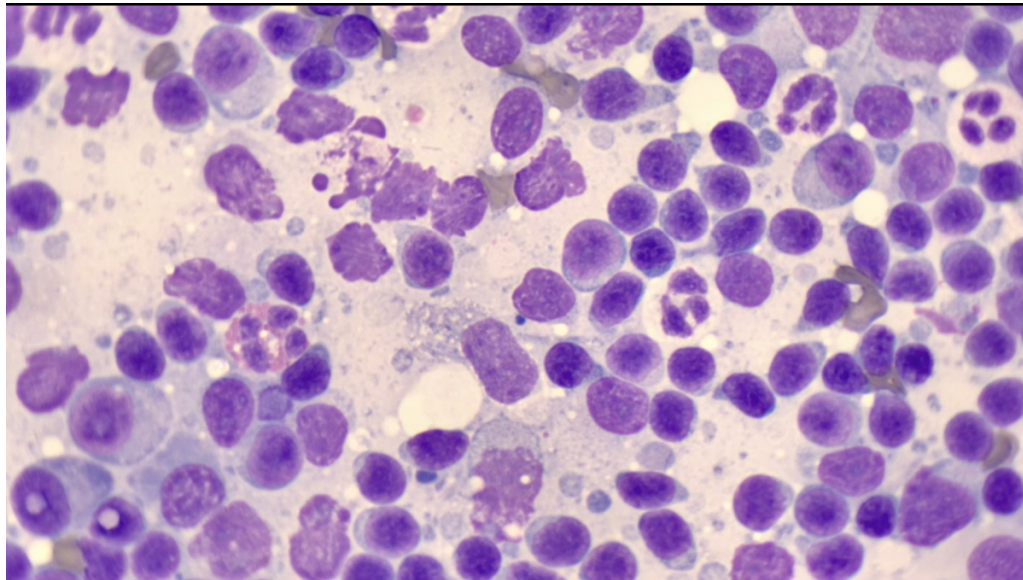
7y

WEIGHT

70#

HOSPITAL NAME

Rotterdam Veterinary
Hospital



REFERRING VET

Dr. Scarpinato

Image shows a representative collection of cells from the groin lump on Brandy. Neutrophils and eosinophils and a macrophage are noted. Most of the lymphocytes are small with nuclei the size of RBCs.

INVOICE NUMBER

873



DATE 1/7/23 The information and recommendations provided are based on the images presented by the referring veterinarian. No evaluation can be communicated regarding pathology that was not visible in the image/video clips provided.

INTERPRETED BY L.D. McGill, DVM, Ph.D., DACVP Thank you for this referral. If the clinical or image interpretation does not parallel your findings or if I can be of any further assistance please contact me.

L.D. McGill, DVM,
Ph.D., DACVP

L.D. McGill, DVM, Ph.D., DACVP
8288 Top of the World Drive
Cottonwood Heights, UT 84121
ldmcgill.vetpath@gmail.com
cell: 801-865-1220

PATIENT

Brandy Hynes

SPECIES

Canine

BREED

Lab Retriever

SEX

Female Spayed

AGE

7y

WEIGHT

70#

HOSPITAL NAME

Rotterdam Veterinary
Hospital

REFERRING VET

Dr. Scarpinato

INVOICE NUMBER

873