



DATE PRESENTING CLINICAL SIGNS

1/6/23

History of mast cell tumor. Ultrasound performed for staging. Liver and and spleen aspirates taken.

INTERPRETED BY CYTOLOGY SUBMISSION

FNA of Spleen

L.D. McGill, DVM,
Ph.D, DACVP

OBSERVATIONS

Spleen: Submitted are 3 excellent videos of excellent collections of cells from the spleen in Moe. The cellularity is consistent with almost all of the cells being round lymphocytes. The majority of these cells are small to intermediate sized lymphocytes. The nuclei are approximately the size of red blood cells. Occasionally they are larger and in the range of three red blood cells. Atypical changes in the cells are not prominent. No mast cells are identified.

PATIENT

Moe Tassone

SPECIES

Canine

INTERPRETATION OF THE FINDINGS & FURTHER RECOMMENDATIONS

Spleen - Prominent lymphoid tissue with no suggestion of mast cells.

BREED

beagle mix

COMMENTS

There is no suggestion of mast cell neoplasia in this tissue. The lymphoid tissue is markedly reactive and thus I am wondering about the possibility of lymphoid nodular hyperplasia. Malignancy cannot be ruled in or completely ruled out. If problems continue in the future, further evaluation of this lymphoid tissue may be of benefit. With the information and observations in the liver and spleen, it appears that the abdominal organs are clear of mast cell neoplasia. Further evaluation of the lymphoid tissue can be considered but very likely this is the result of lymphoid nodular hyperplasia. It was not present in the liver.

AGE

12y

WEIGHT

64.5

HOSPITAL NAME

Rotterdam Veterinary
Hospital

REFERRING VET

Dr. Anna St.Sir

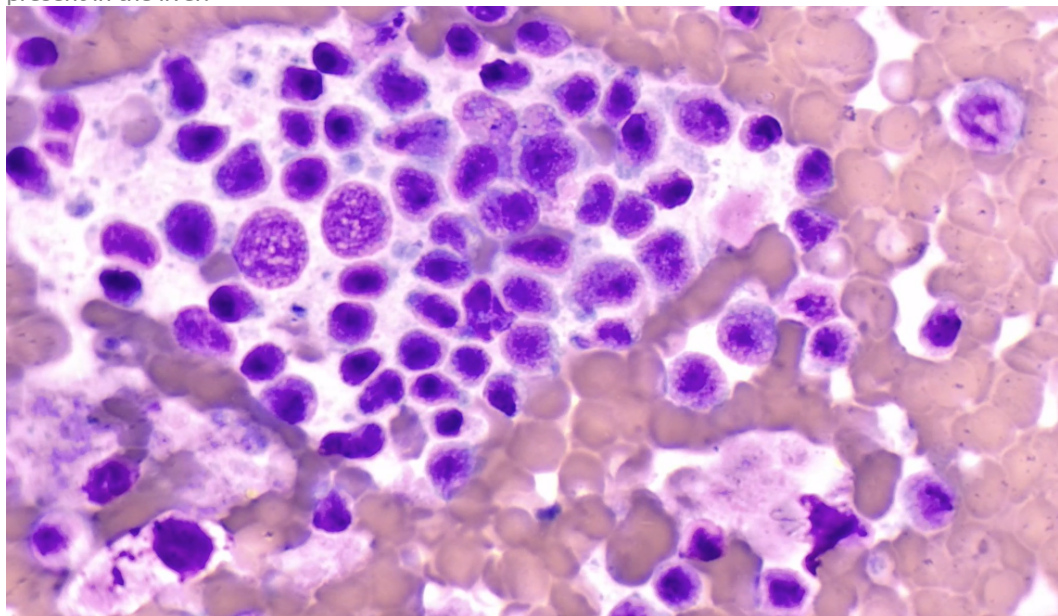


Image shows the lymphoid tissue collected from the spleen in Moe. A large majority of the cells are small mature to intermediate cells. The large cells are likely reactive.

INVOICE NUMBER

40635



DATE

1/6/23

The information and recommendations provided are based on the images presented by the referring veterinarian. No evaluation can be communicated regarding pathology that was not visible in the image/video clips provided.

INTERPRETED BY

L.D. McGill, DVM,
Ph.D, DACVP

Thank you for this referral. If the clinical or image interpretation does not parallel your findings or if I can be of any further assistance, please contact me.

PATIENT

Moe Tassone

L.D. McGill, DVM, Ph.D., DACVP
8288 Top of the World Drive
Cottonwood Heights, UT 84121
ldmcgill.vetpath@gmail.com
cell: 801-865-1220

SPECIES

Canine

BREED

beagle mix

SEX

Male Neutered

AGE

12y

WEIGHT

64.5

HOSPITAL NAME

Rotterdam Veterinary
Hospital

REFERRING VET

Dr. Anna St.Sir

INVOICE NUMBER

40635