



**DATE PRESENTING CLINICAL SIGNS**

2/18/2021: Urinating frequently, presented to Pet Emergency Center for straining/painful to defecate. Was given SQ fluids and prescribed lactulose, tx as outpatient.

1/6/22

Presented for follow up to primary care on 12/22 reporting some improvement since ER visit PE abnormalities: BCS 7/9; heart murmur 3/6 parasternal; really tense to abd palpation,

**INTERPRETED BY**

Radiographs on 12/18 w/Radiologist interp: hepatomegaly, colonic redundancy, poss right caudal abd mass.

L.D. McGill, DVM,  
Ph.D, DACVP

Labs 12/22 at recheck w primary care:

CBC: Normal

Full chems normal other than slight hypochloremia

T4 is normal

**PATIENT**

UA showed cocci and some crystals

Magic Fraser

**CYTOLOGY SUBMISSION**

FNA of Liver

**SPECIES**

**OBSERVATIONS**

Feline

Liver: Submitted are 7 excellent videos of moderate to excellent collections of cells from the liver in Magic. There are several videos that have aggregates of hepatocytes. The hepatocytes are slightly to moderately vacuolated with granularity. There are some areas that suggest that cells are piling upon each other but this is not consistent. In several other videos, there are aggregates of mixed cells including macrophages interspersed with neutrophils. The macrophages have irregular nuclei and some of the macrophages are phagocytic. No bacteria or primary organisms are identified in these areas of inflammation.

**BREED**

Exotic Shorthair

**INTERPRETATION OF THE FINDINGS & FURTHER RECOMMENDATIONS**

**SEX**

Liver - Hepatocellular vacuolization suggesting early hepatocellular lipidosis with pyogranulomatous inflammation.

Male Neutered

**COMMENTS**

**AGE**

The changes in the liver support early metabolic change in the hepatocytes and possibly nodular hyperplasia. I was unable to identify malignant characteristics or changes that would support sepsis.

13yr 10mos

The major cellularity of concern is the pyogranulomatous inflammation. This inflammation is commonly associated with feline infectious peritonitis. PCR can be attempted on these smears for feline coronavirus antigen. Another possibility would be some type of infection or foreign body penetration. There are types of therapy that may be beneficial if FIP is identified. A guarded prognosis is warranted with the observations of the cellularity from these videos.

**WEIGHT**

6.4kg

**HOSPITAL NAME**

Pacific Crest Mobile Vet

**REFERRING VET**

Dr. Harvey/Skagit  
Animal Clinic

**INVOICE NUMBER**

70442



**DATE**

1/6/22

**INTERPRETED BY**

L.D. McGill, DVM,  
Ph.D, DACVP

**PATIENT**

Magic Fraser

**SPECIES**

Feline

**BREED**

Exotic Shorthair

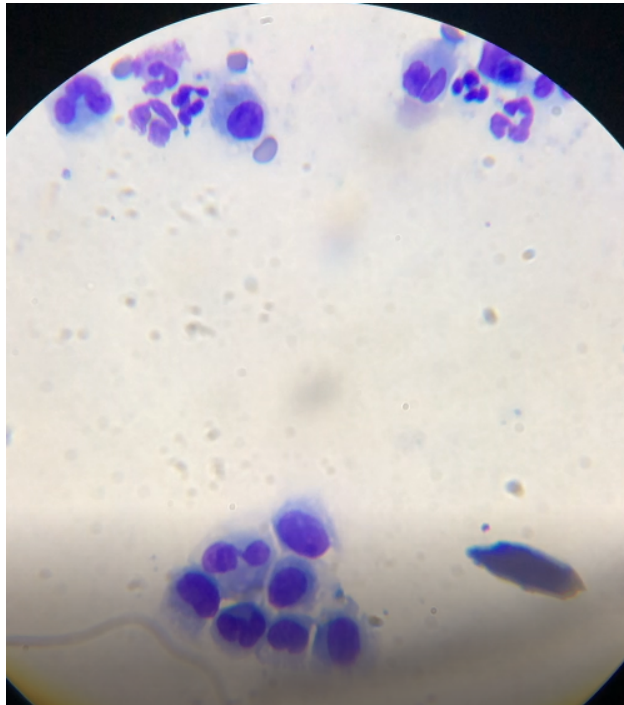


Image shows representative cells collected from the liver in Magic. These cells are macrophages with scattered neutrophils.

**SEX**

Male Neutered

**AGE**

13yr 10mos

**WEIGHT**

6.4kg

**HOSPITAL NAME**

Pacific Crest Mobile Vet

**REFERRING VET**

Dr. Harvey/Skagit  
Animal Clinic

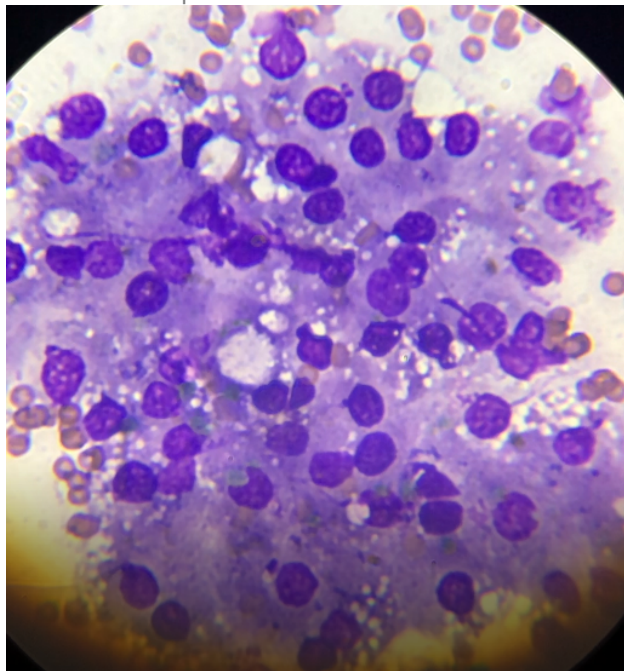


Image shows hepatocytes with vacuolization and possible hyperplasia collected from Magic.

The information and recommendations provided are based on the images presented by the referring veterinarian. No evaluation can be communicated regarding pathology that was not visible in the image/video clips provided.

**INVOICE NUMBER**

70442



**DATE**

1/6/22

Thank you for this referral. If the clinical or image interpretation does not parallel your findings or if I can be of any further assistance please contact me.

**INTERPRETED BY**

L.D. McGill, DVM,  
Ph.D, DACVP

**L.D. McGill, DVM, Ph.D., DACVP**  
8288 Top of the World Drive  
Cottonwood Heights, UT 84121  
ldmcgill.vetpath@gmail.com  
cell: 801-865-1220

**PATIENT**

Magic Fraser

**SPECIES**

Feline

**BREED**

Exotic Shorthair

**SEX**

Male Neutered

**AGE**

13yr 10mos

**WEIGHT**

6.4kg

**HOSPITAL NAME**

Pacific Crest Mobile Vet

**REFERRING VET**

Dr. Harvey/Skagit  
Animal Clinic

**INVOICE NUMBER**

70442