



DATE PRESENTING CLINICAL SIGNS

1/6/22

Vomiting and anorexia for 3 days. Prior chest radiographs highly suspicious of metastatic neoplasia. Globulin of 5.0
Ultrasound has a suspicious hypoechoic area w/ some inflammation and small amount of free fluid in the area of the left caudal limb of pancreas.

INTERPRETED BY

L.D. McGill, DVM,
Ph.D, DACVP

CYTOLOGY SUBMISSION

Pancreas

OBSERVATIONS

Pancreas: Submitted are 13 excellent videos of excellent collections of cells from the lesion in the pancreatic region in Bianca. The cellularity is rather consistent throughout all of these videos. There are large numbers of macrophages, many of which are elongated. The macrophages have pseudopodia and vacuoles in their cytoplasm. There are several videos that demonstrate large numbers of neutrophils. Some of the neutrophils are undergoing degeneration and necrosis. There are many macrophages that are vacuolated with degenerate lipid. This reaction supports chronic inflammation.

PATIENT

Bianca Jones

SPECIES

Canine

INTERPRETATION OF THE FINDINGS & FURTHER RECOMMENDATIONS

Pancreas - Pyogranulomatous and necrotizing pancreatitis

BREED

Argentina Dogo

COMMENTS

These are excellent collections of cells from a degenerative inflamed pancreatic reaction. This is a common response of the pancreas to inflammation since the pancreas is trying to dissolve tissue with release of enzymes. There were scattered structures in the longer videos that suggest the possibility of bacteria but I am unable to confirm that observation. This is very characteristic of a severe chronic necrotizing and pyogranulomatous pancreatitis with a guarded prognosis since we do not know how Bianca will respond to therapy.

SEX

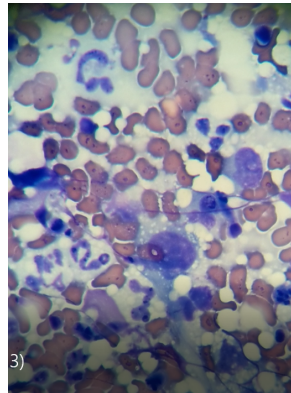
Female Spayed

AGE

7y

WEIGHT

108 lbs



HOSPITAL NAME

Franklin Animal Clinic

Image shows the inflammatory reaction collected from the pancreatic area in Bianca. There are necrotic cells and neutrophils as well as foamy macrophages.

REFERRING VET

Dr. Doverspike

The information and recommendations provided are based on the images presented by the referring veterinarian. No evaluation can be communicated regarding pathology that was not visible in the image/video clips provided.

Thank you for this referral. If the clinical or image interpretation does not parallel your findings or if I can be of any further assistance please contact me.

INVOICE NUMBER

655



DATE L.D. McGill, DVM, Ph.D., DACVP
8288 Top of the World Drive
Cottonwood Heights, UT 84121
ldmcgill.vetpath@gmail.com
cell: 801-865-1220

INTERPRETED BY

L.D. McGill, DVM,
Ph.D., DACVP

PATIENT

Biance Jones

SPECIES

Canine

BREED

Argentina Dogo

SEX

Female Spayed

AGE

7y

WEIGHT

108 lbs

HOSPITAL NAME

Franklin Animal Clinic

REFERRING VET

Dr. Doverspike

INVOICE NUMBER

655