



DATE PRESENTING CLINICAL SIGNS

1/4/23

1/2cm dermal mass

INTERPRETED BY CYTOLOGY SUBMISSION

FNA of Dermal

L.D. McGill, DVM,
Ph.D, DACVP

PATIENT OBSERVATIONS

Orin Lykins

Dermal mass: Submitted are 2 excellent videos of excellent collections of cells from the dermal nodule on Orin. The cellularity is fairly consistent throughout all of the fields. There are large numbers of round cells that are lymphocytes. 60 to 80% of the lymphocytes are small lymphocytes with small nuclei of approximately the size of red blood cells. There are scattered larger cells with larger nuclei but they are not the most numerous. There are rare neutrophils in the collection.

SPECIES

Canine

INTERPRETATION OF THE FINDINGS & FURTHER RECOMMENDATIONS

Dermal mass - Cutaneous lymphoid nodule

BREED

Doberman

COMMENTS

As you suspected, these are almost all lymphocytes. The majority of the cells are small to intermediate sized lymphocytes. Atypical lymphoid cells are few in numbers. This collection could be the result of some type of localized inflammatory process such as an insect or tick bite with inflammation or could also be the result of a regressing histiocytoma. A superficial injection site might cause this cellular collection. I am unable to confirm neoplasia or sepsis. Excision of the nodule would probably be the best follow-up to confirm that something else is not an underlying process in this collection. I did not identify adequate changes in the cells to suggest lymphoma, but the cells are definitely a large numbers of lymphocytes.

SEX

Male

AGE

2y

WEIGHT

84.5

HOSPITAL NAME

Ruidoso Animal Clinic

REFERRING VET

Dr. Amanda Favis

INVOICE NUMBER

40631



DATE

1/4/23

INTERPRETED BY

L.D. McGill, DVM,
Ph.D, DACVP

PATIENT

Orin Lykins

SPECIES

Canine

BREED

Doberman

SEX

Male

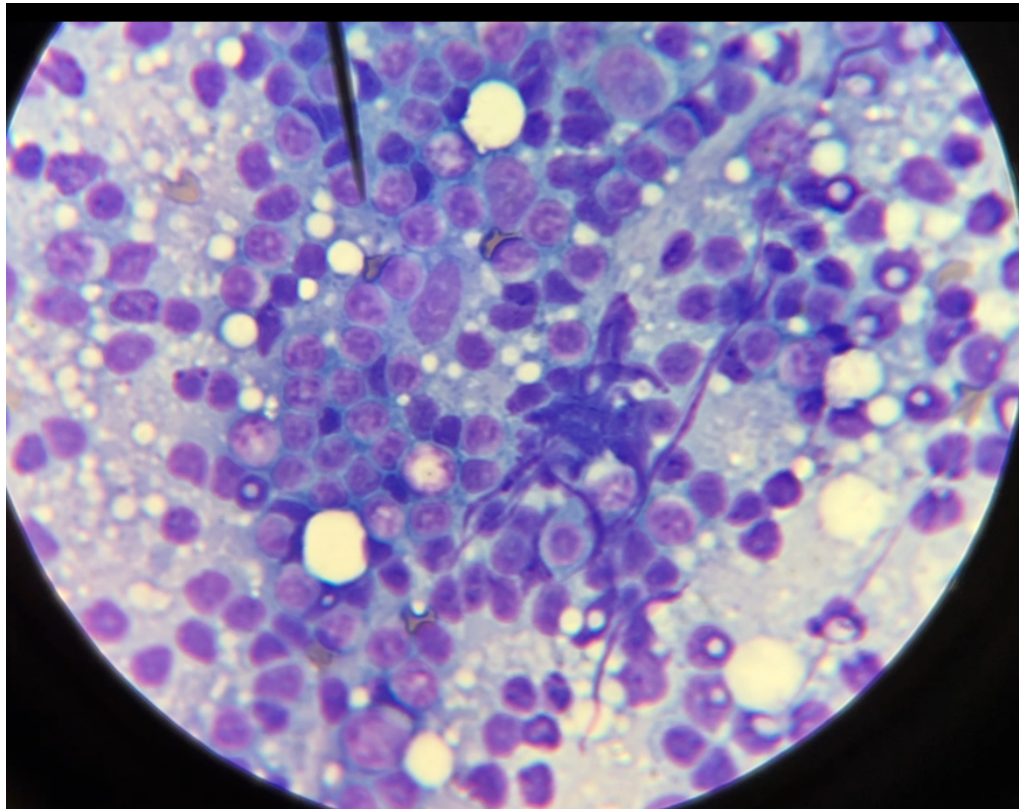


Image shows a representative group of lymphoid cells collected from the skin nodule on Orin. Most of the lymphocytes are small. There are reactive lymphocytes also.

AGE

2y

The information and recommendations provided are based on the images presented by the referring veterinarian. No evaluation can be communicated regarding pathology that was not visible in the image/video clips provided.

WEIGHT

84.5

Thank you for this referral. If the clinical or image interpretation does not parallel your findings or if I can be of any further assistance, please contact me.

HOSPITAL NAME

Ruidoso Animal Clinic

L.D. McGill, DVM, Ph.D., DACVP
8288 Top of the World Drive
Cottonwood Heights, UT 84121
ldmcgill.vetpath@gmail.com
cell: 801-865-1220

REFERRING VET

Dr. Amanda Favis

INVOICE NUMBER

40631