



**DATE** 1/31/22  
**PRESENTING CLINICAL SIGNS**  
Not mildly enlarged liver and spleen; FNA performed on each. Mixed hypoechoic panc pathology, variable intestinal thickening. R/O lymphoma vs other

**INTERPRETED BY** L.D. McGill, DVM, Ph.D, DACVP  
**CYTOLOGY SUBMISSION**  
FNA of Liver & Spleen

**PATIENT** Wyatt Mahoney  
**OBSERVATIONS**  
Liver: Submitted are 4 excellent videos of excellent collections of cells from the liver in Wyatt. There are good aggregates of hepatocytes in many of the fields. The majority of the cells include large numbers of neutrophils with scattered macrophages and lymphocytes. Some of the lymphocytes are large but most are small mature lymphocytes. The neutrophils are irregular and definitely associated with hepatocytes as a major cellularity in the liver.  
**SPECIES** Canine  
Spleen: Submitted are 4 excellent videos of moderate to excellent collections of cells from the spleen in Wyatt. In general the cellularity is mixed with neutrophils, lymphocytes and some nucleated RBCs. There are aggregated platelets scattered throughout the collection. There are large round cells collecting in irregular patterns and individualized throughout the smear. These cells have bluish gray cytoplasm and round nuclei. The cytoplasm is quite prominent in the majority of the cells and in several locations they are clumped. Nucleoli are observed in some cases.  
**BREED** Cocker Spaniel

**SEX** Male Neutered  
**INTERPRETATION OF THE FINDINGS & FURTHER RECOMMENDATIONS**  
Liver - Chronic suppurative or pyogranulomatous hepatitis with hepatocellular granularity.  
Spleen - Mixed cell collection with aggregates of irregular cells suggestive of large cell lymphoma or a histiocytic proliferative process.

**AGE** 10 years  
**COMMENTS**  
The cellularity in the liver is supporting a rather severe chronic inflammatory process. This could be primary or leaking from the pancreatic area or even the intestine. This is a rather severe chronic inflammatory process. I did not identify bacteria but I suspect they are involved. Antibiotic therapy is necessary as soon as possible if further therapy is contemplated.  
**WEIGHT** 33#  
The cellularity in the spleen is more concerning due to the potential of lymphoma. The splenic smears can be submitted for PARR testing to assist in confirming whether lymphoma is present or splenectomy and biopsy of the other organs in the abdominal cavity may be more beneficial in confirming the entire disease process. I am concerned that there is lymphoma or other round cell neoplasm in the spleen and possibly in other organs. These same cells were not identified in the liver. A guarded to unfavorable prognosis is warranted in my opinion.

**HOSPITAL NAME**  
Rockaway Animal Hospital

**REFERRING VET**  
Dr. Maniar

**INVOICE NUMBER**  
70457



**DATE**

1/31/22

**INTERPRETED BY**

L.D. McGill, DVM,  
Ph.D, DACVP

**PATIENT**

Wyatt Mahoney

**SPECIES**

Canine

**BREED**

Cocker Spaniel

**SEX**

Male Neutered




Image shows hepatocytes surrounded by large numbers of neutrophils and macrophages collected from the liver in Wyatt. Rather severe inflammation.

**AGE**

10 years

**WEIGHT**

33#

**HOSPITAL NAME**

Rockaway Animal  
Hospital

**REFERRING VET**

Dr. Maniar

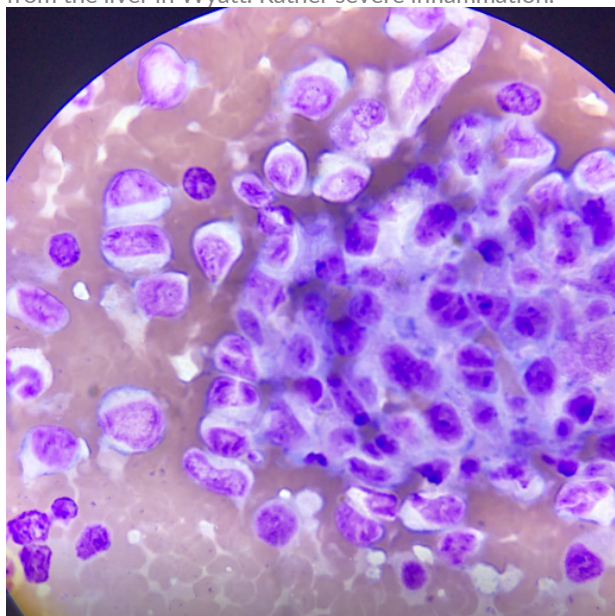


Image shows a group of round cells individualized and clumped in the aspirate from the spleen in Wyatt.

**INVOICE NUMBER**

70457



**DATE** 1/31/22 The information and recommendations provided are based on the images presented by the referring veterinarian. No evaluation can be communicated regarding pathology that was not visible in the image/video clips provided.

**INTERPRETED BY** L.D. McGill, DVM, Ph.D., DACVP Thank you for this referral. If the clinical or image interpretation does not parallel your findings or if I can be of any further assistance please contact me.

L.D. McGill, DVM,  
Ph.D., DACVP

**L.D. McGill, DVM, Ph.D., DACVP**  
8288 Top of the World Drive  
Cottonwood Heights, UT 84121  
ldmcgill.vetpath@gmail.com  
cell: 801-865-1220

**PATIENT**  
Wyatt Mahoney

**SPECIES**

Canine

**BREED**

Cocker Spaniel

**SEX**

Male Neutered

**AGE**

10 years

**WEIGHT**

33#

**HOSPITAL NAME**

Rockaway Animal  
Hospital

**REFERRING VET**

Dr. Maniar

**INVOICE NUMBER**

70457