



**DATE PRESENTING CLINICAL SIGNS**

1/30/22 Pt was transferred to ER yesterday from primary care after presenting for vomiting, lethargy, inappetence. History of chronic urinary tract infections, finished last antibiotics about 4-5 days ago. Mild scleral icterus; ALT 372, ALP 1036, t. bili 1.8 (yesterday)

**INTERPRETED BY** CBC with mild mature neutrophilia, monocytosis and eosinophilia (2.78K)  
Lepto SNAP positive (but was vaccinated 2 weeks ago; PCR is pending to outside lab)  
Abd ultrasound prelim interp by Dr. Daniel:

L.D. McGill, DVM,  
Ph.D, DACVP

**PATIENT**

Matia Jensen

1. Hepatopathy - liver exhibited both chronic and acute criteria with parenchymal remodeling - hypoechoic liver but subjectively mild small in size, vacuolar hepatopathy with non obstructive cholestasis, acute on chronic hepatitis (viral, bacterial, lepto, hepatotoxin, etc), other including possible neoplasia; there appears to be a nodular mass lesion in the area of the mid caudal liver. Its early uniform and similar echogenicity to adjacent remodeled deep liver parenchyma
2. Mild inspissated centralized GB debris, no overt GB or peripheral inflammation - doesn't look like a mucocele
3. Mild CRC - no overt pyelonephritis
4. Gastroenterocolitis pattern

**SPECIES**

Canine

**CYTOLOGY SUBMISSION**  
Liver

**BREED**

Labrador Retriever

**OBSERVATIONS**  
Liver: Submitted are 5 excellent videos and 2 excellent images of moderate to excellent collections of cells from the liver in Matia. The hepatocytes demonstrate vacuolization of most of these cells with some areas demonstrating markedly vacuolated or lipidotic cells. There is prominent lipid throughout the smear in several locations. Interspersed between hepatocytes are inflammatory cells including neutrophils, moderate numbers of eosinophils and lymphocytes. There are also fields that have lymphocytes and macrophages. Malignant criteria are not identified.

**SEX**

Female spayed

**INTERPRETATION OF THE FINDINGS & FURTHER RECOMMENDATIONS**

Liver - Multifocal severe hepatocellular lipidosis and vacuolization with diffuse chronic suppurative, eosinophilic and granulomatous inflammation.

**AGE**

11y

**COMMENTS**

The lipidotic changes and vacuolization in the hepatocytes suggest metabolic liver disease including the potential of steroid hepatopathy. There could also be secondary changes to metabolic problems from the pancreas. There is chronic inflammation which includes eosinophils. This could suggest a parasitic or potentially an acute allergic process. The neutrophils, lymphocytes and macrophages suggest the likelihood of chronic inflammation. In my opinion, you cannot rule out leptospirosis even though there was a vaccination two weeks ago. The organism may have overwhelmed the immunity in Matia. There is no suggestion of malignancy or sepsis. There is definitely evidence of chronic inflammation including allergy and severe lipidosis suggesting metabolic liver disease. At this time, I think inflammation is the major process.

**WEIGHT**

27.7kg

**HOSPITAL NAME**

Animal Emergency Care

**REFERRING VET**

Dr. Callihan

**INVOICE NUMBER**

660



**DATE**

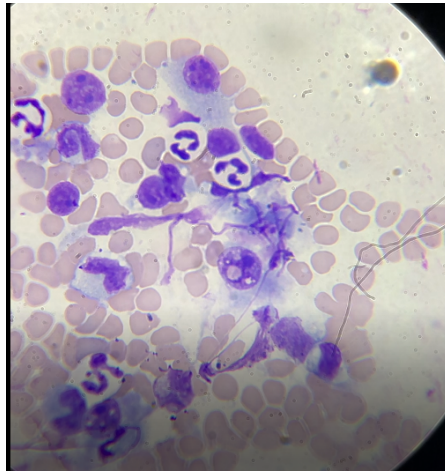
1/30/22

**INTERPRETED BY**

L.D. McGill, DVM,  
Ph.D., DACVP

**PATIENT**

Matia Jensen



**SPECIES**

Canine

**BREED**

Labrador Retriever

**SEX**

Female spayed

**AGE**

11y

**WEIGHT**

27.7kg

**HOSPITAL NAME**

Animal Emergency Care

**REFERRING VET**

Dr. Callihan

**INVOICE NUMBER**

660

Image shows a field of inflammatory cells including neutrophils, macrophages and lymphocytes (pyogranulomatous).

The information and recommendations provided are based on the images presented by the referring veterinarian. No evaluation can be communicated regarding pathology that was not visible in the image/video clips provided.

Thank you for this referral. If the clinical or image interpretation does not parallel your findings or if I can be of any further assistance please contact me.

**L.D. McGill, DVM, Ph.D., DACVP**  
8288 Top of the World Drive  
Cottonwood Heights, UT 84121  
ldmcgill.vetpath@gmail.com  
cell: 801-865-1220