



DATE PRESENTING CLINICAL SIGNS

1/3/23

AUS 12/16/22 coarse liver, moth-eaten appearance. FNA.
ALT 1684, ALP 1969

INTERPRETED BY

CYTOLOGY SUBMISSION

Liver

L.D. McGill, DVM,
Ph.D, DACVP

OBSERVATIONS

Liver: Submitted are 12 excellent videos of moderate to excellent collections of cells from the liver in Cooper. The hepatocytes demonstrate a rather diffuse vacuolization to granularity. There are scattered spindle cell to slightly eosinophilic cells. The cells suggest fibrosis. Other types of inflammatory cells such as neutrophils are lymphocytes are few in numbers. There are scattered macrophages with a foamy to vacuolated cytoplasm. The hepatocytes demonstrate slight anisokaryosis.

PATIENT

Cooper Devanney

INTERPRETATION OF THE FINDINGS & FURTHER RECOMMENDATIONS

Liver - Hepatocellular vacuolization and granularity with fibrosis and possible nodular hyperplasia

SPECIES

Canine

COMMENTS

The cellularity in this collection is supporting extremely good collections of hepatocytes. Hepatocellular vacuolization and granularity suggests metabolic or other types of changes. There very likely is hepatic fibrosis with nodular hyperplasia. I was unable to identify any changes that would support neoplasia or sepsis. The cellularity at this time is not diagnostic of any primary process in the liver. Continued evaluation for changes that might affect the liver in secondary process is encouraged. Copper evaluations may be beneficial in further evaluation in this case. A guarded prognosis is warranted.

BREED

Scottish Terrier

SEX

Male Neutered

AGE

11y

WEIGHT

19#

HOSPITAL NAME

Berkeley Heights Animal
Hospital

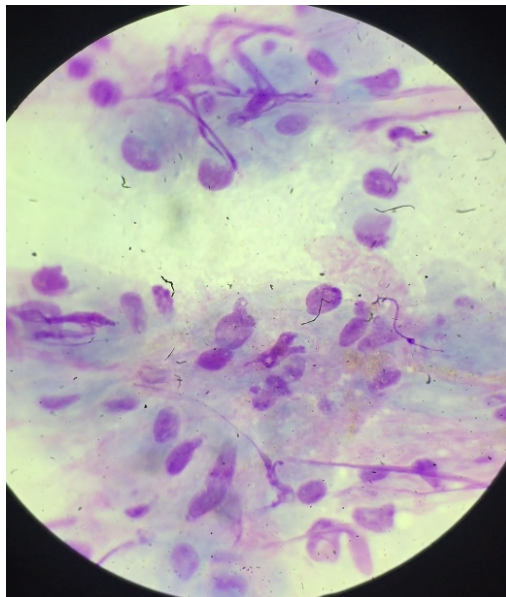


Image shows a group of hepatocytes with some spindle cell accumulation in this collection from Cooper. Neoplastic change is not identified.

REFERRING VET

Dr. Seltzer

The information and recommendations provided are based on the images presented by the referring veterinarian. No evaluation can be communicated regarding pathology that was not visible in the image/video clips provided.

INVOICE NUMBER

872



DATE

1/3/23

Thank you for this referral. If the clinical or image interpretation does not parallel your findings or if I can be of any further assistance please contact me.

INTERPRETED BY

L.D. McGill, DVM,
Ph.D, DACVP

L.D. McGill, DVM, Ph.D., DACVP
8288 Top of the World Drive
Cottonwood Heights, UT 84121
ldmcgill.vetpath@gmail.com
cell: 801-865-1220

PATIENT

Cooper Devanney

SPECIES

Canine

BREED

Scottish Terrier

SEX

Male Neutered

AGE

11y

WEIGHT

19#

HOSPITAL NAME

Berkeley Heights Animal
Hospital

REFERRING VET

Dr. Seltzer

INVOICE NUMBER

872