



DATE PRESENTING CLINICAL SIGNS

1/3/22

Stark was presented with acute hematemesis about 2 weeks ago. Routine blood test showed HCT of 10. The cause of hematemesis was gastric ulcers and they were surgically treated. At that time, the cause of the anemia was thought to be the blood loss because of ulcers. After two weeks, hematology was done again to know the anemia status and it is still the same, HCT 10. The cat is clinically healthy and eating well.

INTERPRETED BY

L.D. McGill, DVM,
Ph.D, DACVP

CYTOLOGY SUBMISSION

Blood smear

PATIENT OBSERVATIONS

Wadeema Stark

Blood smear: Submitted are several images of the blood smear collected from Stark. There are red blood cells in all of the images with a few nucleated white blood cells. The white blood cells are neutrophils and lymphocytes that appear to be within normal limits. The red blood cells are pleomorphic in some fields. They are within normal limits in other fields. I did not identify parasites. There were platelets. The pleomorphism of the red cells could be due to clotting problems or due to smearing of the blood or blood sitting in the tube for a period prior to smearing.

SPECIES

Feline

INTERPRETATION OF THE FINDINGS & FURTHER RECOMMENDATIONS

Blood smear - Pleomorphic red blood cells possibly due to smearing alterations or due to red cells being caught within organs or clot material.

BREED

Persian cross

COMMENTS

These blood smears in some locations suggest older blood. If this blood had time to sit in the tube for a period, then the pleomorphic red cells may be the result of sitting in the tube. Otherwise some of those changes can be the result of becoming entrapped in clot material in some other location in the body. I did not identify any changes that would support neoplasia or parasites. Re-collection and making blood smears immediately upon collecting the blood may be of benefit in this case. The images are slightly out of focus as well which contributes to confusion in interpretation. Make sure you focus on your camera and not on the eyepieces when taking photos.

SEX

Male

AGE

4 y

WEIGHT

4.44 kg

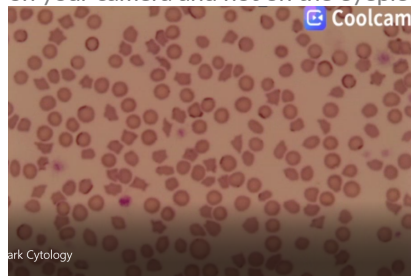


Image shows RBCs with some pleomorphism of the cells. The strung out RBCs are a concern. There is no suggestion of neoplasia or parasites.

HOSPITAL NAME

City Veterinary Clinic
Alain

The information and recommendations provided are based on the images presented by the referring veterinarian. No evaluation can be communicated regarding pathology that was not visible in the image/video clips provided.

REFERRING VET

Dr. Inam ul haq

Thank you for this referral. If the clinical or image interpretation does not parallel your findings or if I can be of any further assistance please contact me.

INVOICE NUMBER

653



DATE

1/3/22

L.D. McGill, DVM, Ph.D., DACVP
8288 Top of the World Drive
Cottonwood Heights, UT 84121
ldmcgill.vetpath@gmail.com
cell: 801-865-1220

INTERPRETED BY

L.D. McGill, DVM,
Ph.D, DACVP

PATIENT

Wadeema Stark

SPECIES

Feline

BREED

Persian cross

SEX

Male

AGE

4 y

WEIGHT

4.44 kg

HOSPITAL NAME

City Veterinary Clinic
Alain

REFERRING VET

Dr. Inam ul haq

INVOICE NUMBER

653