



DATE PRESENTING CLINICAL SIGNS

1/3/22

Presented on ER Friday 12/31 for continued inappetence and lethargy. Had been vaccinated on Wednesday, started vomiting and was treated with Cerenia by ref vet, stopped vomiting but still lethargic, inappetent.

INTERPRETED BY

L.D. McGill, DVM,
Ph.D, DACVP

nitial lab work Fri ALT 744, ALKP >2000, tBili 4.8; next day improved slightly with ALT and ALKP but tBili 5.8; amylase and lipase very elevated throughout; today slightly improved in ALT and ALKP and tBili is normal; Clinically looking very good, eating since evening of admit (Fri night) but continues with exquisite abd pain rt cranial quadrant

Abd ultrasound most striking for signs pancreatitis and poss beginning necrosis, also concerns for abnormal liver and spleen

PATIENT

Max MacDonald

CYTOLOGY SUBMISSION

Liver
Lymph Node
Pancreas
Spleen

SPECIES

Canine

BREED

Lab

OBSERVATIONS
Liver: Submitted are 6 excellent videos of cells collected from the liver in Max. The cellularity is moderate in many of the videos. One or 2 videos have large numbers of hepatocytes. The hepatocytes demonstrate granularity with minimal vacuolization. In one of the videos there are aggregates of cells that demonstrate anisocytosis and anisokaryosis. These cells are somewhat vacuolated and aggregated. They suggest carcinoma of some type.

SEX

Male Neutered

Pancreas: Submitted are 6 excellent videos of cells collected from the pancreas in Max. The majority of the videos include large numbers of erythrocytes with mixed inflammatory cells including lymphocytes and neutrophils. There are scattered packets of irregular epithelial cells. These epithelial cells demonstrate slight anisocytosis and anisokaryosis. Many of these cells are granulated. This aggregated cellularity is irregular.

AGE

14y

Spleen: Submitted are 3 excellent videos of cells collected from the spleen in Max. The cellularity is mixed. There are nucleated RBCs interspersed with scattered lymphocytes and neutrophils. Cells with malignant criteria are not identified. All of the cellularity is irregular and a common mixed cell collection in the spleen.

WEIGHT

38kg

Lymph node: Submitted are 5 excellent videos of cells collected from the lymph node in Max. There is an excellent collection of cells in all of these videos. Lymphocytes are prominent. Many of the fields have small mature lymphocytes with prominent dark nuclei. The small cells are interspersed with larger cells and some of the larger cells are irregular. One video has cellularity that could support lymphoma but this is not consistent through all of the videos. This suggests that the lymph node is markedly reactive.

HOSPITAL NAME

Animal Emergency Care

INTERPRETATION OF THE FINDINGS & FURTHER RECOMMENDATIONS

Liver - Diffuse hepatocellular granularity with a packet of cells suggesting carcinoma or neuroendocrine tumor

REFERRING VET

Dr. Becky Callihan

Pancreas - Chronic inflammation and hemorrhage with a few cells suggesting possible carcinoma
Spleen - Mild chronic splenitis with hematopoiesis

DVM/AEC

Lymph node - Markedly reactive lymphoid tissue with one field suggesting early lymphoma but not diagnostic.

INVOICE NUMBER

70440



DATE COMMENTS

1/3/22

The cellularity in the image that I have attached from the liver and the cellularity from the one packet of cells identified in the pancreas are suspicious for carcinoma or an outside possibility of neuroendocrine tumor. There is mainly inflammation in the liver and pancreas. The hepatocellular granularity is a secondary nonspecific process.

INTERPRETED BY

L.D. McGill, DVM,
Ph.D, DACVP

The changes in the lymph node are of concern but are most likely the result of a markedly reactive lymphoid tissue. Video LN 1 has some changes that could be consistent with early lymphoma but this is not carried through to the other videos although there are few cells that are suspicious in those videos. The suspicious lymphoid cells are less than 50% in all of the videos.

PATIENT

Max MacDonald

The changes in the spleen are those of splenitis and extra medullary hematopoiesis. There really is no change of malignancy or primary disease in the spleen.

With all of these changes, the major problems appear to be in the liver and pancreas. In order to confirm the diagnosis, exploratory and biopsy is required. I am concerned about the potential of a carcinoma affecting the pancreas in the liver but the cellularity is not confirmatory in this collection of small aggregates of irregular cells. A guarded prognosis is definitely in order. Image shows the irregular cells collected in 1 video from the liver in Max. Note the anisocytosis and anisokaryosis.

SPECIES

Canine

BREED

Lab

SEX

Male Neutered

AGE

14y

WEIGHT

38kg

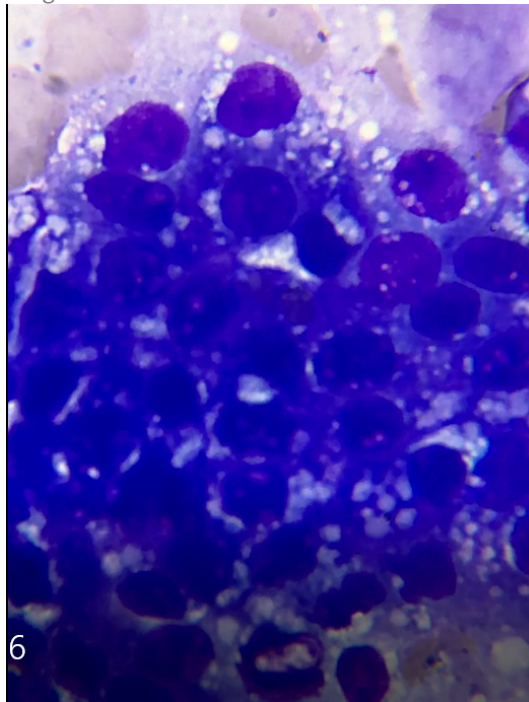


Image shows the irregular cells collected in 1 video from the liver in Max. Note the anisocytosis and anisokaryosis.

HOSPITAL NAME

Animal Emergency Care

REFERRING VET

Dr. Becky Callihan

DVM/AEC

INVOICE NUMBER

70440



DATE

1/3/22

INTERPRETED BY

L.D. McGill, DVM,
Ph.D, DACVP

PATIENT

Max MacDonald

SPECIES

Canine

BREED

Lab

SEX

Male Neutered

AGE

14y

WEIGHT

38kg

HOSPITAL NAME

Animal Emergency Care

REFERRING VET

Dr. Becky Callihan

DVM/AEC

INVOICE NUMBER

70440

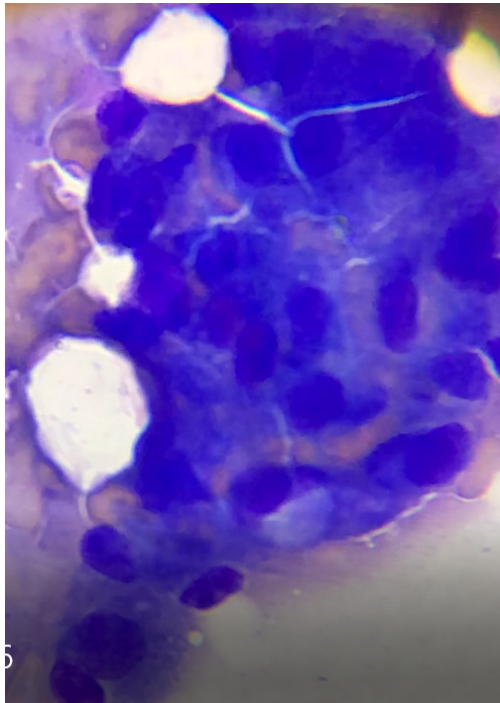


Image shows one of the irregular packets of cells collected from the pancreas in Max. There is irregularity in the cells.

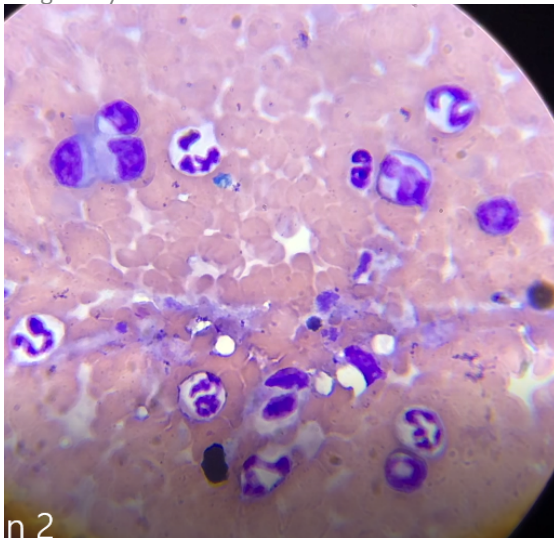
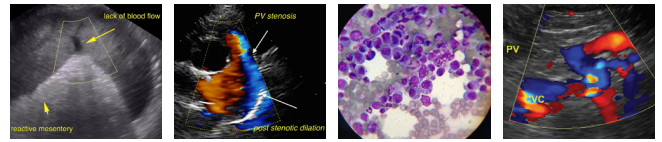


Image shows the cellularity in the spleen collected from Max.



DATE

1/3/22

INTERPRETED BY

L.D. McGill, DVM,
Ph.D, DACVP

PATIENT

Max MacDonald

SPECIES

Canine

BREED

Lab

SEX

Male Neutered

AGE

14y

WEIGHT

38kg

HOSPITAL NAME

Animal Emergency Care

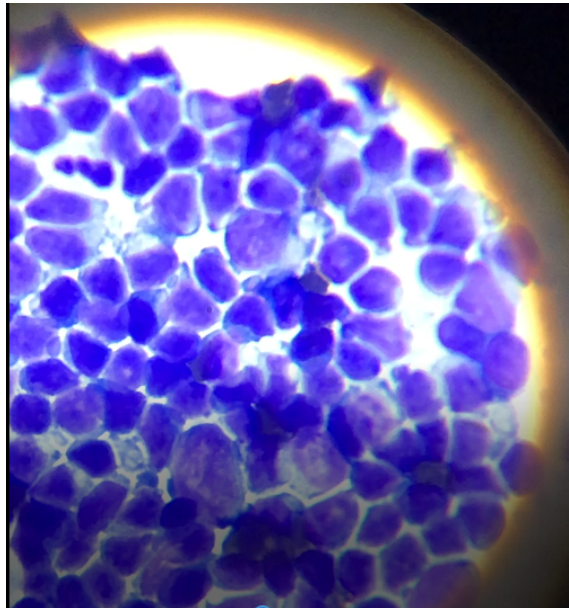
REFERRING VET

Dr. Becky Callihan

DVM/AEC

INVOICE NUMBER

70440



This image shows a group of lymphocytes collected from Max. Many of the lymphocytes are small mature lymphocytes.

The information and recommendations provided are based on the images presented by the referring veterinarian. No evaluation can be communicated regarding pathology that was not visible in the image/video clips provided.

Thank you for this referral. If the clinical or image interpretation does not parallel your findings or if I can be of any further assistance, please contact me.

L.D. McGill, DVM, Ph.D., DACVP
8288 Top of the World Drive
Cottonwood Heights, UT 84121
ldmcgill.vetpath@gmail.com
cell: 801-865-1220