



DATE PRESENTING CLINICAL SIGNS

1/27/22

Pt presented for acute onset decreased appetite and lethargy, weight loss; owner reported initially pt appeared to want to eat but would pick up food/drip it. Oral exam was normal. ultrasound requested for further assessment regarding acute elevation ALT 1900. No known toxin exposures.

INTERPRETED BY Pt is current on preventive care including Lepto Vax and Lepto testing is negative

L.D. McGill, DVM,
Ph.D, DACVP

CYTOLOGY SUBMISSION

Sample text

PATIENT

Ivy Entrikin

OBSERVATIONS

Liver: Submitted are 6 excellent videos of moderate collections of cells from the liver in Ivy. The hepatocytes are darkly stained with scattered vacuoles and granular cytoplasm. The hepatocytes appear to be growing in normal patterns. There are no criteria of malignancy in this collection of hepatocytes. There are aggregates of inflammatory cells in the surrounding red blood cells. Some of the cells are macrophages interspersed with neutrophils. There are scattered lymphoid cells but the majority of the inflammatory cells are macrophages and neutrophils.

SPECIES

Canine

BREED

Labrador Retriever

INTERPRETATION OF THE FINDINGS & FURTHER RECOMMENDATIONS

Liver - Mild hepatocellular vacuolization and granularity with evidence of pyogranulomatous inflammation.

SEX

FS

COMMENTS

The cellular changes in this collection support relative normal hepatocytes with slight vacuolization suggesting a secondary change. This can be due to problems in the pancreas, intestine or other abdominal organs. There is no suggestion of malignancy or sepsis in any of this collection but there is a suggestion of pyogranulomatous inflammation. This could be secondary to inflammation draining to the liver from other organs or there could be a primary inflammatory process in the liver. If problems continue, further evaluation for a source for chronic inflammation and problems in other organs in the abdominal cavity is encouraged.

AGE

5yr

WEIGHT

32kg

HOSPITAL NAME

Pacific Crest Mobile Vet

REFERRING VET

Dr. Harvey/Skagit
Animal Clinic

INVOICE NUMBER

70456



DATE

1/27/22

INTERPRETED BY

L.D. McGill, DVM,
Ph.D, DACVP

PATIENT

Ivy Entrikin

SPECIES

Canine

BREED

Labrador Retriever

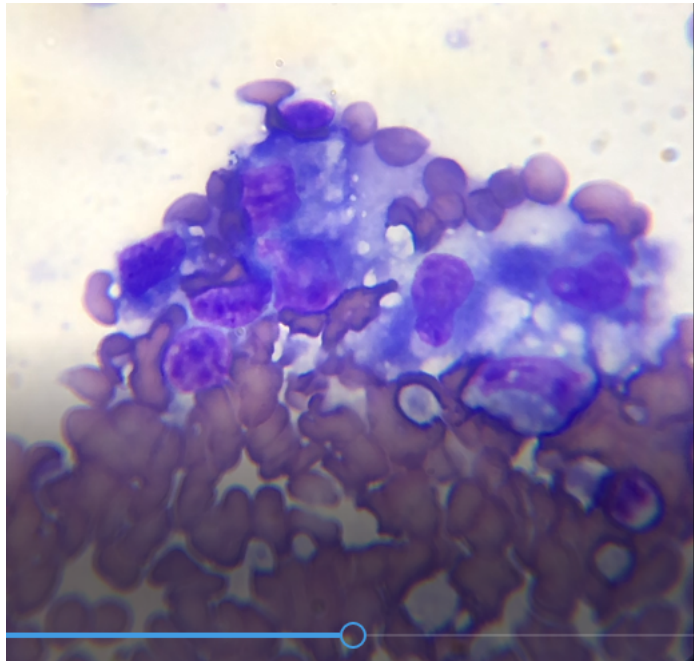


Image shows a group of macrophages collected from the liver in Ivy. Other fields have good hepatocytes and neutrophils.

SEX

FS

The information and recommendations provided are based on the images presented by the referring veterinarian. No evaluation can be communicated regarding pathology that was not visible in the image/video clips provided.

AGE

5yr

Thank you for this referral. If the clinical or image interpretation does not parallel your findings or if I can be of any further assistance please contact me.

WEIGHT

32kg

L.D. McGill, DVM, Ph.D., DACVP
8288 Top of the World Drive
Cottonwood Heights, UT 84121
ldmcgill.vetpath@gmail.com
cell: 801-865-1220

HOSPITAL NAME

Pacific Crest Mobile Vet

REFERRING VET

Dr. Harvey/Skagit
Animal Clinic

INVOICE NUMBER

70456