



DATE PRESENTING CLINICAL SIGNS

1/25/23

acute orbital swelling right eye, sever conjunctivitis. FNA of swelling upper right eyelid

INTERPRETED BY CYTOLOGY SUBMISSION

L.D. McGill, DVM,
Ph.D, DACVP

FNA of swelling upper right eyelid

PATIENT

Barron Villari

OBSERVATIONS

Eyelid Swelling: Submitted are 5 excellent videos of cells collected from the eyelid on Barron. The cellularity consists of massive numbers of neutrophils with marked smudged nuclear debris throughout the collection. This is indicated by the streaking purple color which is degenerate nucleated debris. There are scattered macrophages and rare keratinized cells. Malignant characteristics are not identified. The macrophages have a foamy cytoplasm.

SPECIES

Feline

INTERPRETATION OF THE FINDINGS & FURTHER RECOMMENDATIONS

Eyelid swelling - Pyogranulomatous and necrotizing inflammation with no suggestion of malignancy.

BREED

DSH

COMMENTS

The cellularity supports a severe chronic inflammatory process. There are massive numbers of neutrophils and there is degenerate nuclear debris. The specific cause for the reaction is not identified. It could be some type of foreign body penetration or even a hair shaft driven into the region. Trauma or infection could also be part of the process. An outside possibility is a central area of necrosis in a neoplastic process. Treatment for inflammation and bacterial infection is encouraged. A guarded prognosis is warranted since we do not know the cause for this rather severe and necrotizing process.

SEX

Male Neutered

AGE

16 years

WEIGHT

5.8#

HOSPITAL NAME

Animal Care Centers of
Landing

REFERRING VET

Dr. Villari

INVOICE NUMBER

40650



DATE

1/25/23

INTERPRETED BY

L.D. McGill, DVM,
Ph.D, DACVP

PATIENT

Barron Villari

SPECIES

Feline

BREED

DSH

SEX

Male Neutered

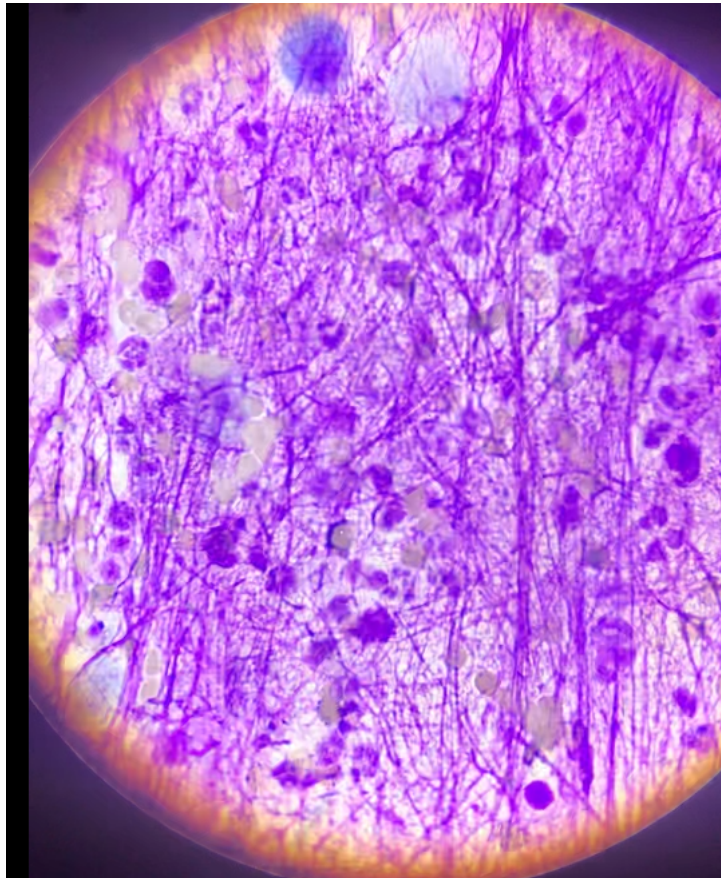


Image shows neutrophils and degenerate nuclear debris with scattered macrophages collected from the eyelid on Barron. There is no suggestion of malignancy.

AGE

16 years

The information and recommendations provided are based on the images presented by the referring veterinarian. No evaluation can be communicated regarding pathology that was not visible in the image/video clips provided.

WEIGHT

5.8#

Thank you for this referral. If the clinical or image interpretation does not parallel your findings or if I can be of any further assistance, please contact me.

HOSPITAL NAME

Animal Care Centers of
Landing

L.D. McGill, DVM, Ph.D., DACVP
8288 Top of the World Drive
Cottonwood Heights, UT 84121
ldmcgill.vetpath@gmail.com
cell: 801-865-1220

REFERRING VET

Dr. Villari

INVOICE NUMBER

40650