



**DATE PRESENTING CLINICAL SIGNS**

1/24/23

Hx of a pea sized nodule at distal medial aspect of pinna. Suspect histiocytoma

**INTERPRETED BY CYTOLOGY SUBMISSION**

L.D. McGill, DVM,  
Ph.D, DACVP

FNA of Dermal

**PATIENT OBSERVATIONS**

LT Moran

Nodule from the distal medial ear: Submitted are 7 excellent images of cells collected from the nodule on the ear on LT. The cellularity consists of large numbers of round cells. The round cells, in general, have centrally located nuclei. The nuclei are round to oblong. There is slight granularity and fluid buildup in the cytoplasm which is minimal. These cells have a fried egg appearance. There are scattered lymphocytes in the collection as well.

**SPECIES**

Canine

**INTERPRETATION OF THE FINDINGS & FURTHER RECOMMENDATIONS**

**BREED**

Bulldog

Nodule from the distal medial ear - Histiocytoma

**COMMENTS**

**SEX**

MI

The cellularity is characteristic of histiocytoma cells. They often have a fried egg appearance and these demonstrate that pattern. There is prominent cytoplasm and the nuclei are rather consistent. There is a small amount of inflammation associated with this collection which is not unusual. As you well know, these growths may regress on their own. This aspiration may be of benefit in assisting in regression. A favorable prognosis is expected with this mass. I do not expect any type of progressive neoplastic process from the cells.

**AGE**

1y

**WEIGHT**

85 lbs.

**HOSPITAL NAME**

Torch Lake Veterinary  
Clinic

**REFERRING VET**

Dr. Adrienne Waffle

**INVOICE NUMBER**

40647

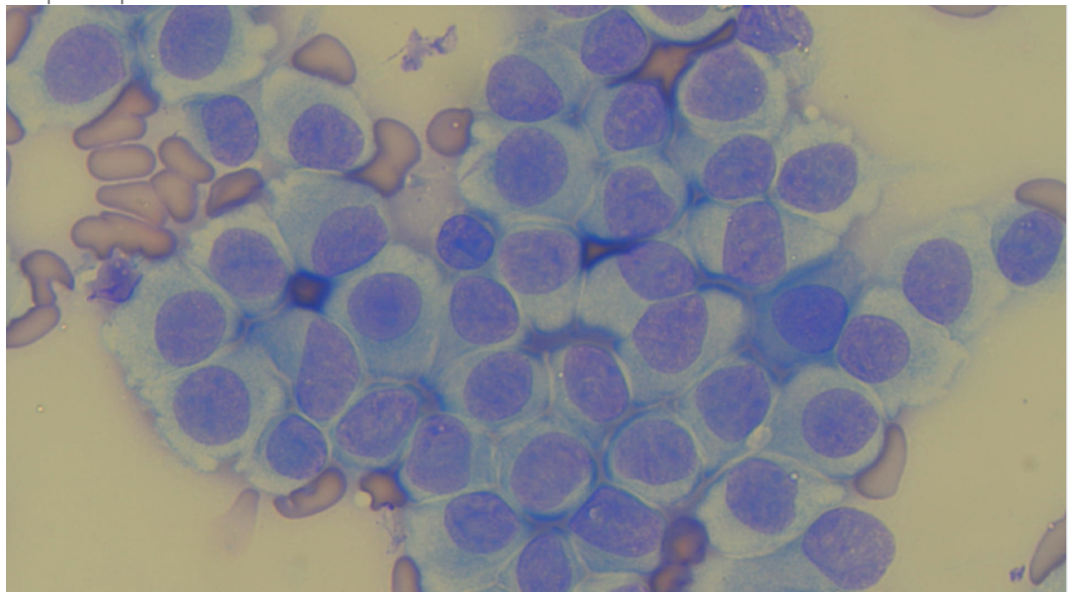


Image shows histiocytoma cells collected from the ear nodule on LT. Note the central located nuclei.



**DATE** 1/24/23 The information and recommendations provided are based on the images presented by the referring veterinarian. No evaluation can be communicated regarding pathology that was not visible in the image/video clips provided.

**INTERPRETED BY** L.D. McGill, DVM, Ph.D., DACVP Thank you for this referral. If the clinical or image interpretation does not parallel your findings or if I can be of any further assistance, please contact me.

L.D. McGill, DVM,  
Ph.D., DACVP

**L.D. McGill, DVM, Ph.D., DACVP**  
8288 Top of the World Drive  
Cottonwood Heights, UT 84121  
ldmcgill.vetpath@gmail.com  
cell: 801-865-1220

**PATIENT**  
LT Moran

**SPECIES**  
Canine

**BREED**  
Bulldog

**SEX**  
MI

**AGE**  
1y

**WEIGHT**  
85 lbs.

**HOSPITAL NAME**  
Torch Lake Veterinary  
Clinic

**REFERRING VET**  
Dr. Adrienne Waffle

**INVOICE NUMBER**  
40647