



DATE PRESENTING CLINICAL SIGNS

1/24/23

ADR, Weight Loss and Poor Appetite
Leukocytosis w/ neutrophilia
Abdominal U/S (Sonopath Report): Large cystic mass originating from the left liver. Spleen possibly has a micronodular pattern suggestive of metastatic disease.

INTERPRETED BY

L.D. McGill, DVM,
Ph.D, DACVP

CYTOLOGY SUBMISSION

FNA of Cyst on the liver

PATIENT

Athena Custer

OBSERVATIONS

Cyst on the liver: Submitted are nine excellent videos of moderate collections of cells from the cystic structure on the liver in Athena. There is a mixture of cells throughout the collection. Neutrophils, lymphocytes, macrophages and even spindle cells are identified. The last two videos had good collections of reactive mesothelial cells from the surface. The reaction therefore is mixed throughout the cellular collection. Malignant characteristics or sepsis cannot be identified.

SPECIES

Canine

BREED

Boxer

INTERPRETATION OF THE FINDINGS & FURTHER RECOMMENDATIONS

Cyst on the liver - Pyogranulomatous inflammation with necrosis and granulation tissue proliferation.

SEX

Female Spayed

COMMENTS

The cellularity in this collection supports a chronic inflammatory process occurring within this cystic reaction. This is an excellent collection of the wall whereas the fluid in the center may not be beneficial in determining the process. The wall of the reaction is inflammatory in nature. The reason for this inflammation is not confirmed. Necrosis is present as well as evidence of chronic inflammation and granulation tissue. There is no suggestion of sepsis in this collection. Exploratory and elimination of the cyst may be beneficial in treatment, but this could be an interesting surgery. A guarded prognosis is warranted since we do not know the cause for this chronic inflammatory process. It could be a dilated biliary duct cyst or some other process including a parasitic reaction. Mast cells were identified in the first video.

AGE

9 years

WEIGHT

74lbs

HOSPITAL NAME

Franklin Animal Clinic
Inc.

REFERRING VET

Dr. Sam Doverspike

INVOICE NUMBER

40646



DATE

1/24/23

INTERPRETED BY

L.D. McGill, DVM,
Ph.D, DACVP

PATIENT

Athena Custer

SPECIES

Canine

BREED

Boxer

SEX

Female Spayed

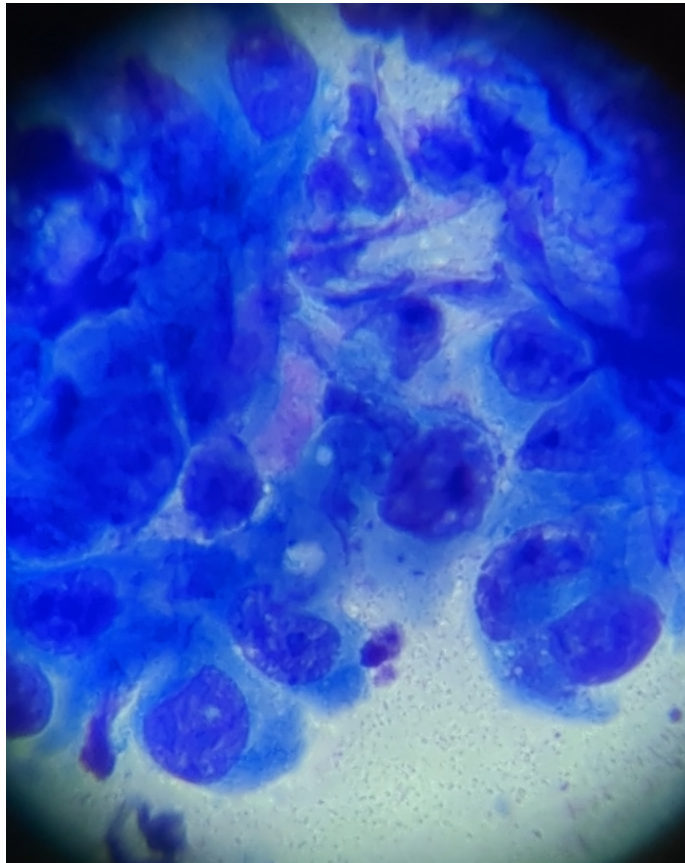


Image shows a group of macrophages with vacuolated and granulated cytoplasm. Other inflammatory cells were noted in other videos from Athena.

AGE

9 years

WEIGHT

74lbs

The information and recommendations provided are based on the images presented by the referring veterinarian. No evaluation can be communicated regarding pathology that was not visible in the image/video clips provided.

Thank you for this referral. If the clinical or image interpretation does not parallel your findings or if I can be of any further assistance, please contact me.

HOSPITAL NAME

Franklin Animal Clinic
Inc.

L.D. McGill, DVM, Ph.D., DACVP
8288 Top of the World Drive
Cottonwood Heights, UT 84121
ldmcgill.vetpath@gmail.com
cell: 801-865-1220

REFERRING VET

Dr. Sam Doverspike

INVOICE NUMBER

40646