



**DATE PRESENTING CLINICAL SIGNS**

1/23/22

Presented today as transfer from primary care with complaint of 3-4 d anorexia. No known toxin exposures or gastric indiscretions; history urinary issues.  
moderate neutropenia (1.99k) mild monocytosis (0.75k), Tbili (3.1), ALT (391)  
Lytes: WNL

**INTERPRETED BY**

L.D. McGill, DVM,  
Ph.D, DACVP

**CYTOLOGY SUBMISSION**

Liver

**OBSERVATIONS**

Liver: Submitted are 6 excellent videos of moderate to excellent collections of cells from the liver in Tchai. Where there are hepatocytes, the hepatocytes are demonstrating small irregular vacuolization. They are interspersed with round cells. The majority of the fields include a mixture of round cells that have minimal cytoplasm. The nuclei are varied in size and shape. Some of the cytoplasm is more prominent and is bluish gray. These cells have the characteristics of large irregular atypical lymphoid cells.

**PATIENT**

Tchai Gawloski

**SPECIES**

Feline

**INTERPRETATION OF THE FINDINGS & FURTHER RECOMMENDATIONS**

Liver - High-grade lymphoma with secondary mild hepatocellular lipidosis.

**COMMENTS**

**BREED**

DLH

The cellularity in this collection from Tchai, demonstrates good collections of hepatocytes but the majority of the cells are highly irregular and quite large lymphoid cells. Some of the nuclei are extremely pleomorphic. The cellularity is associated with hepatocytes and interspersed with red blood cells. Immunophenotyping these cells can be undertaken with parr testing on these slides or re-collection may be beneficial. My understanding is that this immunophenotyping is not as beneficial in the cat as it is in the dog. An unfavorable prognosis is warranted in my opinion. Chemotherapy may be of benefit in prolonging Tchai's life. I suspect that other organs besides the liver are also involved.

**SEX**

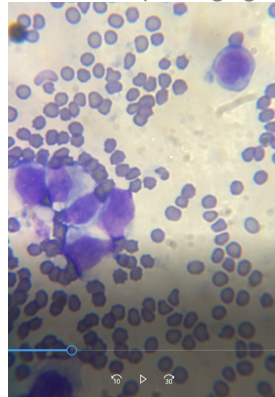
Male Neutered

**AGE**

5y

**WEIGHT**

6.7kg



**HOSPITAL NAME**

Animal Emergency Care

Image shows a group of large lymphoid cells collected from the liver in Tchai. Note the large nuclei and irregular nucleoli.

**REFERRING VET**

Dr. Callihan

The information and recommendations provided are based on the images presented by the referring veterinarian. No evaluation can be communicated regarding pathology that was not visible in the image/video clips provided.

Thank you for this referral. If the clinical or image interpretation does not parallel your findings or if I can be of any further assistance please contact me.

**INVOICE NUMBER**

657



**DATE** L.D. McGill, DVM, Ph.D., DACVP

1/23/22  
8288 Top of the World Drive  
Cottonwood Heights, UT 84121  
ldmcgill.vetpath@gmail.com  
cell: 801-865-1220

**INTERPRETED BY**

L.D. McGill, DVM,  
Ph.D., DACVP

**PATIENT**

Tchai Gawloski

**SPECIES**

Feline

**BREED**

DLH

**SEX**

Male Neutered

**AGE**

5y

**WEIGHT**

6.7kg

**HOSPITAL NAME**

Animal Emergency Care

**REFERRING VET**

Dr. Callihan

**INVOICE NUMBER**

657