



**DATE PRESENTING CLINICAL SIGNS**

1/20/23

1 week hx of anorexia and cough. Coughing up "chunks that look like pneumonia".  
Lost 9 lbs since March 2022.

**INTERPRETED BY**

L.D. McGill, DVM,  
Ph.D, DACVP

**CYTOLOGY SUBMISSION**

Pulmonary collection

**OBSERVATIONS**

Pulmonary collection: Submitted are 17 excellent images of minimal nucleated cellular collections from this sample from Luke. The sample has the appearance of tracheal material with a mixture of cells. There is mucus and debris throughout the collection. Neutrophils are readily identified as are macrophages. Many of the macrophages are large and vacuolated. There is a suggestion of bacteria in the background. There are structures that suggest the possibility of fungal hyphae but I cannot be certain about those structures. There is no suggestion of neoplasia.

**PATIENT**

Luke Nurenberg

**INTERPRETATION OF THE FINDINGS & FURTHER RECOMMENDATIONS**

**SPECIES**

Pulmonary collection - Pyogranulomatous and mucoid inflammation

**CA**

**COMMENTS**

The cellularity suggests material that would come from the trachea. There is mucus and there is degenerate debris. There are macrophages present that show vacuolated cytoplasm and thus they are phagocytizing secreted material. There are adequate numbers of neutrophils and scattered lymphocytes to suggest chronic inflammation. Bacterial culture can be undertaken but that can be difficult on this type of sample. From the material we have it appears to be a chronic inflammatory process and treatment for inflammation and infection is encouraged. This may require long-term antibiotic therapy and therapy for pneumonia. A guarded prognosis is warranted due to the chronicity.

**BREED**

Great Pyrenees

**SEX**

MI

**AGE**

3y

**WEIGHT**

108

**HOSPITAL NAME**

Torch Lake Veterinary  
Clinic

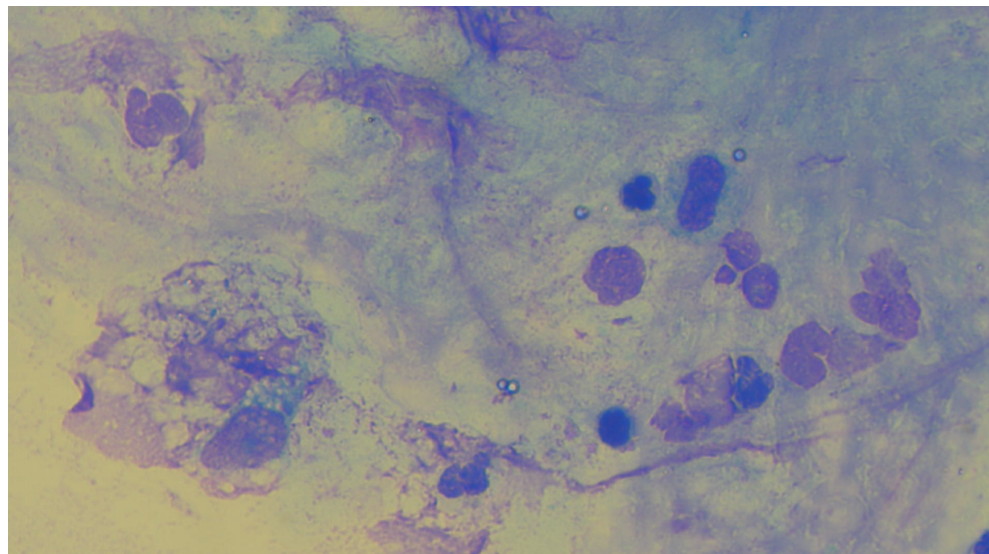


Image shows a large macrophage and several neutrophils with mucus strands and debris collected from Luke. There is a suggestion of bacteria in the background.

**REFERRING VET**

Dr. Waffle

The information and recommendations provided are based on the images presented by the referring veterinarian. No evaluation can be communicated regarding pathology that was not visible in the image/video clips provided.

**INVOICE NUMBER**

880



**DATE** 1/20/23 Thank you for this referral. If the clinical or image interpretation does not parallel your findings or if I can be of any further assistance please contact me.

**INTERPRETED BY** L.D. McGill, DVM, Ph.D., DACVP  
8288 Top of the World Drive  
Cottonwood Heights, UT 84121  
ldmcgill.vetpath@gmail.com  
cell: 801-865-1220

**PATIENT**  
Luke Nurenberg

**SPECIES**  
CA

**BREED**  
Great Pyrenees

**SEX**  
MI

**AGE**  
3y

**WEIGHT**  
108

**HOSPITAL NAME**  
Torch Lake Veterinary  
Clinic

**REFERRING VET**  
Dr. Waffle

**INVOICE NUMBER**  
880