



DATE PRESENTING CLINICAL SIGNS

1/20/23

Patient presented 1/18/23 with lethargy and dehydration. Hasn't been eating well. Painful on abdominal palpation. Has history of pancreatitis and asthma. On abdominal ultrasound - enlarged coarse hyperechoic liver, pancreas is enlarged, irregular and hypoechoic. U/S-guided FNA liver and pancreas were obtained.

INTERPRETED BY

.

L.D. McGill, DVM,
Ph.D, DACVP

CYTOLOGY SUBMISSION

FNA of Liver

PATIENT

Emmett Coronato

OBSERVATIONS

Liver: Submitted are 23 excellent images of large numbers of cells from the liver in Emmett. The cells consist of hepatocytes with marked vacuolization and lipidosis. There are scattered inflammatory cells and scattered red blood cells. The inflammatory cells are mixed with neutrophils and lymphocytes.

SPECIES

Feline

The lipid accumulation within hepatocytes and macrophages is extensive. There appears to be some free lipid in the smears as well.

BREED

DSH

INTERPRETATION OF THE FINDINGS & FURTHER RECOMMENDATIONS

Liver - Severe hepatocellular lipodosis with mild inflammation consistent with feline fatty liver syndrome

SEX

Male Neutered

COMMENTS

The cellularity in this collection is strongly characteristic of feline fatty liver syndrome and marked hepatic lipodosis. There is mild inflammation. Feline fatty liver syndrome in the cat is commonly associated with pancreatitis and thus in my opinion this is likely a case of pancreatitis with secondary liver changes. The mild inflammation around hepatocytes would be consistent with an ascending inflammatory process from the pancreas. There is no suggestion of malignancy or sepsis. A guarded prognosis is warranted since pancreatitis can be difficult to treat. To treat the liver changes, reestablishing alimentionation is important.

AGE

7 yrs

WEIGHT

13.3 lb

HOSPITAL NAME

Rotterdam Veterinary
Hospital

REFERRING VET

Dr. Anna St.Sir

INVOICE NUMBER

40644



DATE

1/20/23

INTERPRETED BY

L.D. McGill, DVM,
Ph.D., DACVP

PATIENT

Emmett Coronato

SPECIES

Feline

BREED

DSH

SEX

Male Neutered

AGE

7 yrs

WEIGHT

13.3 lb

HOSPITAL NAME

Rotterdam Veterinary
Hospital

REFERRING VET

Dr. Anna St.Sir

INVOICE NUMBER

40644

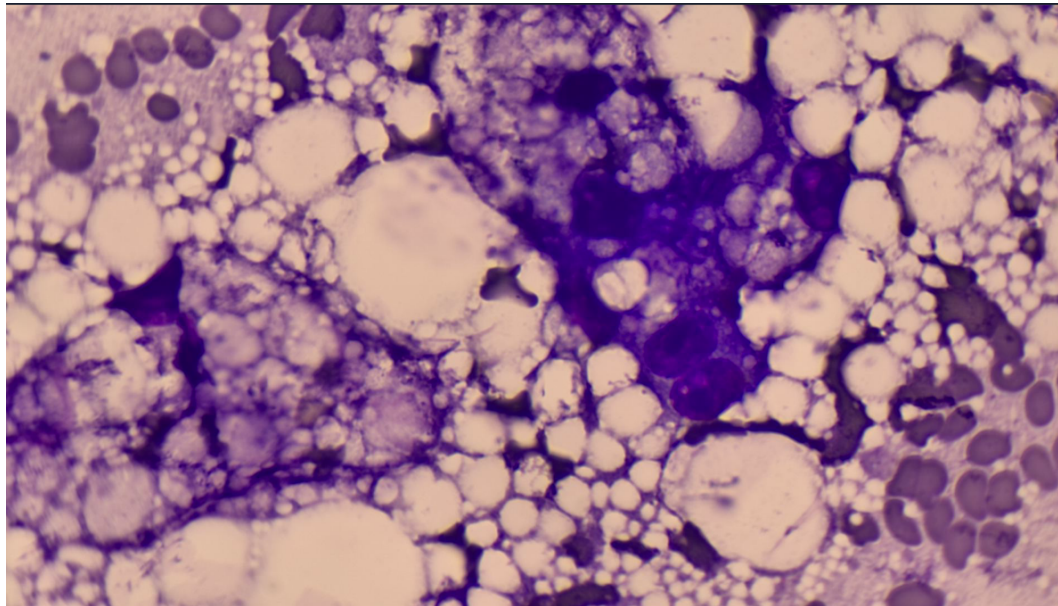


Image shows hepatocytes with various sizes of lipid vacuoles and free lipid interspersed through the collection from the liver in Emmett.

The information and recommendations provided are based on the images presented by the referring veterinarian. No evaluation can be communicated regarding pathology that was not visible in the image/video clips provided.

Thank you for this referral. If the clinical or image interpretation does not parallel your findings or if I can be of any further assistance, please contact me.

L.D. McGill, DVM, Ph.D., DACVP
8288 Top of the World Drive
Cottonwood Heights, UT 84121
ldmcgill.vetpath@gmail.com
cell: 801-865-1220