



**DATE PRESENTING CLINICAL SIGNS**

1/20/23

Patient presented 1/18/23 with lethargy and dehydration. Hasn't been eating well. Painful on abdominal palpation. Has history of pancreatitis and asthma. On abdominal ultrasound - enlarged coarse hyperechoic liver, pancreas is enlarged, irregular and hypoechoic. U/S-guided FNA liver and pancreas were obtained.

**INTERPRETED BY**

L.D. McGill, DVM,  
Ph.D, DACVP

**CYTOLOGY SUBMISSION**

FNA of Pancreas

**PATIENT**

Emmett Coronato

**OBSERVATIONS**

Pancreas: Submitted are 25 excellent images of cells collected from the pancreas in Emmett. The majority of the cells are packets of epithelial cells most characteristic of pancreatic acinar cells. There are scattered inflammatory cells such as neutrophils, lymphocytes, and even macrophages. The epithelial cells demonstrate rather uniform nuclei and cytoplasm. They do not demonstrate characteristics of malignancy. They certainly could be hyperplastic. There is mild inflammation. Hemorrhage is prominent.

**SPECIES**

Feline

**BREED**

DSH

**INTERPRETATION OF THE FINDINGS & FURTHER RECOMMENDATIONS**

Pancreas - Suggestive of nodular hyperplasia or possible pancreatic acinar adenoma with chronic inflammation and hemorrhage.

**SEX**

Male Neutered

**COMMENTS**

The cellularity in this collection suggests the likelihood of nodular hyperplasia or possible pancreatic acinar adenoma. There is no suggestion of carcinoma but there is evidence of chronic inflammation. The inflammation easily could be from chronic pancreatitis. I was unable to identify changes that would support sepsis. At this time, I am most concerned about the possibility of pancreatitis with the secondary area of nodular hyperplasia or an adenoma. Continued treatment for pancreatitis and reestablishing alimentation is encouraged in Emmett. A guarded prognosis is still warranted. Exploratory may be required to confirm mass at this time.

**AGE**

7 yrs

**WEIGHT**

13.3 lb

**HOSPITAL NAME**

Rotterdam Veterinary  
Hospital

**REFERRING VET**

Dr. Anna St.Sir

**INVOICE NUMBER**

40643



**DATE**

1/20/23

**INTERPRETED BY**

L.D. McGill, DVM,  
Ph.D., DACVP

**PATIENT**

Emmett Coronato

**SPECIES**

Feline

**BREED**

DSH

**SEX**

Male Neutered

**AGE**

7 yrs

**WEIGHT**

13.3 lb

**HOSPITAL NAME**

Rotterdam Veterinary  
Hospital

**REFERRING VET**

Dr. Anna St.Sir

**INVOICE NUMBER**

40643

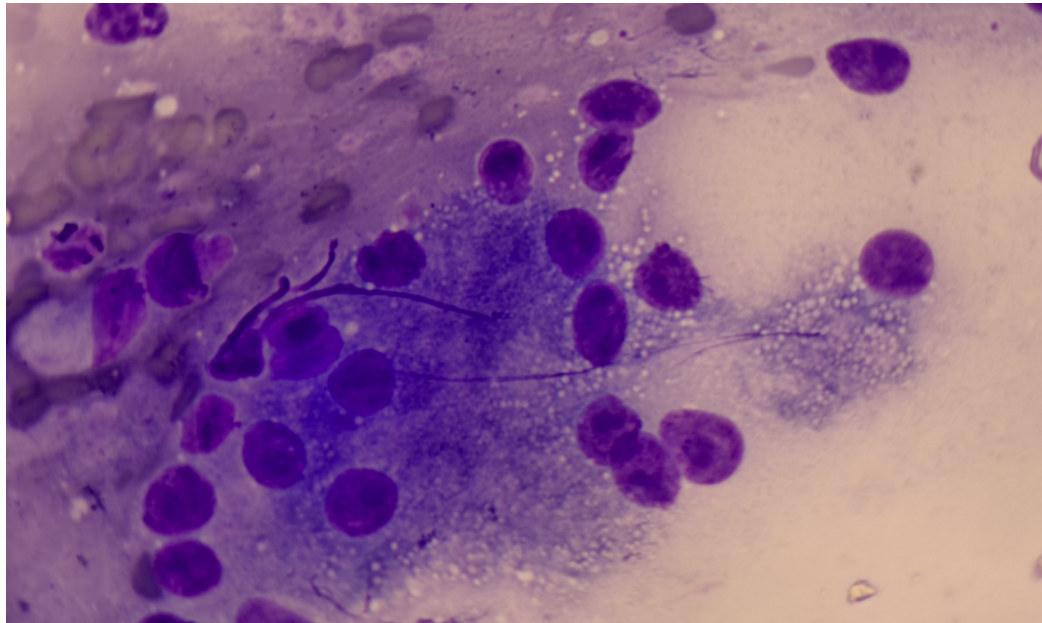


Image shows a representative collection of pancreatic acinar cells with a few inflammatory cells collected from the pancreas in Emmett. Note the uniformity of the nuclei.

The information and recommendations provided are based on the images presented by the referring veterinarian. No evaluation can be communicated regarding pathology that was not visible in the image/video clips provided.

Thank you for this referral. If the clinical or image interpretation does not parallel your findings or if I can be of any further assistance, please contact me.

**L.D. McGill, DVM, Ph.D., DACVP**  
8288 Top of the World Drive  
Cottonwood Heights, UT 84121  
ldmcgill.vetpath@gmail.com  
cell: 801-865-1220