



**DATE** **PRESENTING CLINICAL SIGNS**  
1/19/23 8mm pink, superficial raised, hairless mass on ventral neck with firmer, subcutaneous tissue underneath (12mm)

**INTERPRETED BY** **CYTOLOGY SUBMISSION**  
L.D. McGill, DVM, Ph.D, DACVP FNA of Ventral neck mass

**PATIENT** **OBSERVATIONS**  
Jovi Heller Ventral neck mass: Submitted are 6 excellent videos of excellent collections of cells from the ventral neck mass on Jovi. The cellularity demonstrates packeted cells with slight anisokaryosis. Some of the nuclear characteristics are elongated. There are no specific mitotic figures, and the cellularity is not as aggressive as can be identified in malignant skin lesions. In some areas the cells demonstrate a chain-like pattern. No other specific differentiation is identified.

**SPECIES**  
Canine

**BREED** **INTERPRETATION OF THE FINDINGS & FURTHER RECOMMENDATIONS**  
shihtzu Ventral neck mass - Strongly suggestive of basal cell tumor (trichoepithelioma)

**SEX** **COMMENTS**  
Male Neutered The cellularity supports a proliferative process of epithelial cells, and these cells appear to be basaloid in nature. This type of mass is expected to respond well to excision. It is likely very well demarcated. Good margins are always encouraged with this type of a mass, but they do not have to be as wide as mast cell tumors. I expect a favorable prognosis with excision of this lesion from Jovi.

**AGE**  
14y  
**WEIGHT**  
14.8

**HOSPITAL NAME**  
Rotterdam Veterinary Hospital

**REFERRING VET**  
Dr. Anna St.Sir

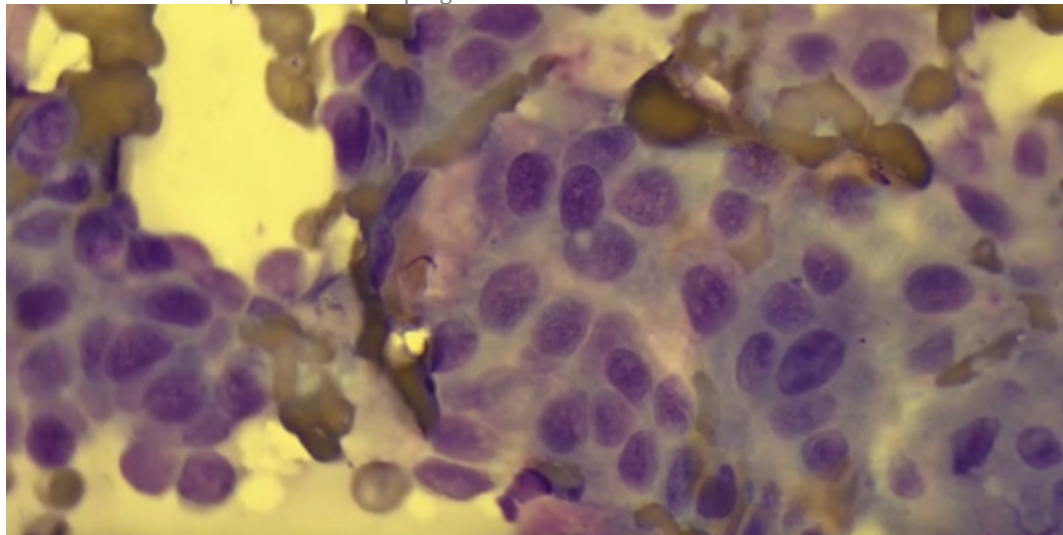


Image shows a representative group of cells collected from the ventral neck mass on Jovi. Some nuclei are elongated and there is a chain like pattern to growth.

**INVOICE NUMBER**  
40642



**DATE** 1/19/23 The information and recommendations provided are based on the images presented by the referring veterinarian. No evaluation can be communicated regarding pathology that was not visible in the image/video clips provided.

**INTERPRETED BY** L.D. McGill, DVM, Ph.D., DACVP Thank you for this referral. If the clinical or image interpretation does not parallel your findings or if I can be of any further assistance, please contact me.

L.D. McGill, DVM,  
Ph.D., DACVP

**L.D. McGill, DVM, Ph.D., DACVP**  
8288 Top of the World Drive  
Cottonwood Heights, UT 84121  
ldmcgill.vetpath@gmail.com  
cell: 801-865-1220

**PATIENT**  
Jovi Heller

**SPECIES**  
Canine

**BREED**  
shihtzu

**SEX**  
Male Neutered

**AGE**  
14y

**WEIGHT**  
14.8

**HOSPITAL NAME**  
Rotterdam Veterinary  
Hospital

**REFERRING VET**  
Dr. Anna St.Sir

**INVOICE NUMBER**  
40642