



DATE PRESENTING CLINICAL SIGNS

1/13/22

Moderately growing mass on flank - concern for soft tissue sarcoma

CYTOLOGY SUBMISSION

Flank mass

INTERPRETED BY

L.D. McGill, DVM,
Ph.D., DACVP

OBSERVATIONS

Flank mass: Submitted are 10 images of cells collected from the flank mass on Aria. The majority of the cells are demonstrating spindloid patterns with elongated nuclei. Some of the nuclei are more rounded than others. The nuclei show nucleoli in some cases. There are scattered inflammatory cells that include neutrophils and rare macrophages. The spindloid cells demonstrate tails extending out from the nuclei.

PATIENT

Aria Megarity

INTERPRETATION OF THE FINDINGS & FURTHER RECOMMENDATIONS

Flank mass - Spindle cell proliferation consistent with soft tissue sarcoma.

SPECIES

Canine

COMMENTS

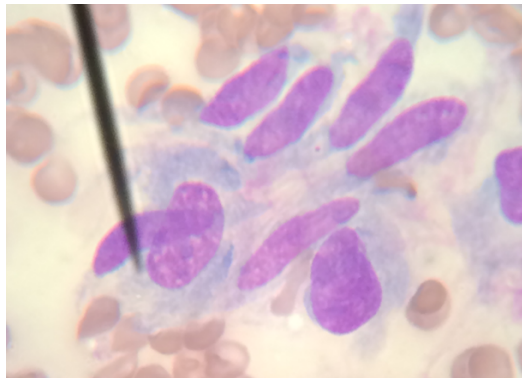
The cellularity in this collection is most consistent with a soft tissue sarcoma particularly with the irregular nuclei. Excision of the mass is encouraged. Another possibility would be very active granulation tissue. There is some inflammation. Excision and biopsy of the tissue will be required to confirm the diagnosis since there appears to be a limitation of numbers of cells in these smears. Soft tissue sarcomas can be difficult to collect cells but granulation tissue is even harder to collect cells. Most soft tissue sarcomas in the dog do not metastasize readily. Excision is encouraged but the age of Aria should be taken into consideration.

BREED

Golden Retriever

SEX

Female Spayed



AGE

14y

WEIGHT

69 lbs

Image shows anisokaryosis in the spindle cells collected from the flank mass on Aria. Some of the nuclei show nucleoli.

HOSPITAL NAME

Ruidoso Animal Clinic

The information and recommendations provided are based on the images presented by the referring veterinarian. No evaluation can be communicated regarding pathology that was not visible in the image/video clips provided.

Thank you for this referral. If the clinical or image interpretation does not parallel your findings or if I can be of any further assistance please contact me.

REFERRING VET

Dr. Favis

L.D. McGill, DVM, Ph.D., DACVP

8288 Top of the World Drive
Cottonwood Heights, UT 84121

INVOICE NUMBER

656

ldmcgill.vetpath@gmail.com
cell: 801-865-1220



DATE

1/13/22

INTERPRETED BY

L.D. McGill, DVM,
Ph.D, DACVP

PATIENT

Aria Megarity

SPECIES

Canine

BREED

Golden Retriever

SEX

Female Spayed

AGE

14y

WEIGHT

69 lbs

HOSPITAL NAME

Ruidoso Animal Clinic

REFERRING VET

Dr. Favis

INVOICE NUMBER

656