



DATE PRESENTING CLINICAL SIGNS

1/11/23

Concerned owner brought in their overweight cat that had some fatty lumps covering over right ribcage, ~3" x 2". Was told by DVM that it is most likely fat. Owner still wanted confirmation. After staining slides everything washed off and there are only a few cells to view. Two pictures are viewed under oil setting and the rest are on low power

INTERPRETED BY

L.D. McGill, DVM,
Ph.D, DACVP

CYTOLOGY SUBMISSION

Subcutaneous mass

OBSERVATIONS

PATIENT

Knight Setu

Subcutaneous mass: Submitted are 9 images of collections of material from the subcutaneous site in Knight. There is minimal cellularity in the collection. There is extensive lipid and smudged material throughout the collection. There are packets of erythrocytes scattered throughout but adipocytes are rare. Other specific cellularity is not identified.

INTERPRETATION OF THE FINDINGS & FURTHER RECOMMENDATIONS

SPECIES

Feline

Subcutaneous mass - Prominent lipid with very few adipocytes and some erythrocytes.

COMMENTS

The cellularity in this collection is minimal. Where there are cells, there are red blood cells and there is some suggestion of a very few adipocytes. Lipid is a major collection in this aspiration. Lipid can occur with lipomas or fat tissues alone. In this instance it appears that this collection is a benign collection of fat and lipid with very few adipocytes. It may be a lipoma but it could also just be a localized fat depot.

BREED

DSH

SEX

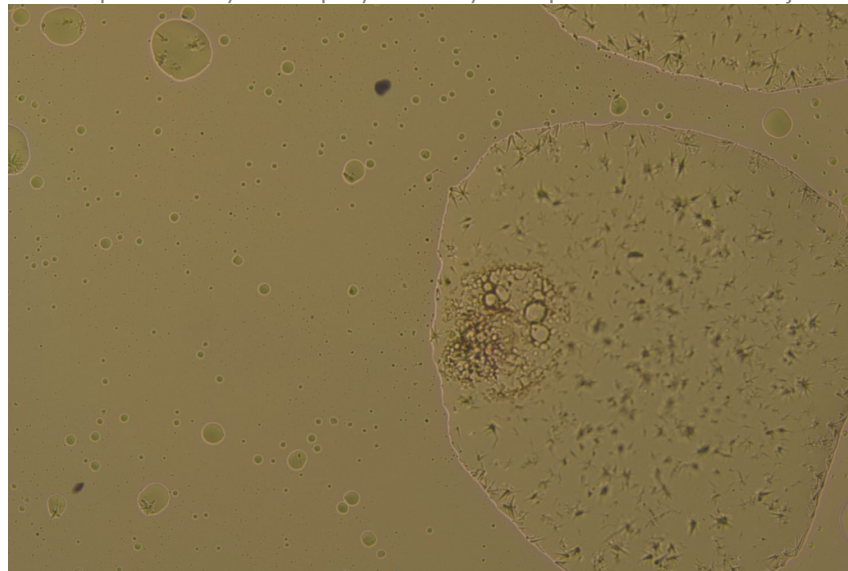
Male Neutered

AGE

9y

WEIGHT

23 lbs



HOSPITAL NAME

Central Veterinary
Hospital

Image shows lipid and a possible adipocyte collected from Knight. No other specific cells are noted.

REFERRING VET

Dr. Goeldner

The information and recommendations provided are based on the images presented by the referring veterinarian. No evaluation can be communicated regarding pathology that was not visible in the image/video clips provided.

Thank you for this referral. If the clinical or image interpretation does not parallel your findings or if I can be of any further assistance please contact me.

INVOICE NUMBER

875



DATE L.D. McGill, DVM, Ph.D., DACVP

1/11/23
8288 Top of the World Drive
Cottonwood Heights, UT 84121
ldmcgill.vetpath@gmail.com
cell: 801-865-1220

INTERPRETED BY

L.D. McGill, DVM,
Ph.D., DACVP

PATIENT

Knight Setu

SPECIES

Feline

BREED

DSH

SEX

Male Neutered

AGE

9y

WEIGHT

23 lbs

HOSPITAL NAME

Central Veterinary
Hospital

REFERRING VET

Dr. Goeldner

INVOICE NUMBER

875