



**DATE PRESENTING CLINICAL SIGNS**

1/11/23 A soft, dermal nodule of about 2cm in diameter was noticed in the cranial sternal region. FNA of the nodule was taken and submitted for examination

**INTERPRETED BY CYTOLOGY SUBMISSION**

L.D. McGill, DVM, Ph.D, DACVP FNA of Subcutaneous mass

**PATIENT OBSERVATIONS**

Buddy Claire Subcutaneous mass: Submitted is one video of material collected from this nodule on Buddy. There is minimal if any nucleated cellularity. The majority of the material consists of protein with possible lipid and stain debris. No other significant cellular change is identified. I was unable to identify adipocytes or any specific cells.

**SPECIES INTERPRETATION OF THE FINDINGS & FURTHER RECOMMENDATIONS**

Canine Subcutaneous mass - Protein and lipid with no specific nucleated cellularity.

**BREED COMMENTS**

Cross breed The collection is only protein and amorphous material which could be lipid. I did not identify any nucleated cells. This can be the type of aspirate from a lipoma but could also be the result of a cystic structure such as a sweat gland cyst. With this collection, the lesion is likely benign and excision is encouraged. There are some cases of very low grade spindle cell tumors where this may be the only material collected. Either way excision of the nodule is encouraged for therapy. There is no suggestion of mast cell neoplasia or other types of round cell proliferation. If this is a lipoma, these lesions may occur in other sites independently.

**SEX**

Male

**AGE**

9y

**WEIGHT**

14.1kg

**HOSPITAL NAME**

City veterinary clinic, Abu Dhabi, Khalifa City

**REFERRING VET**

Dr. Inam ul haq DVM MRCVS

**INVOICE NUMBER**

40637

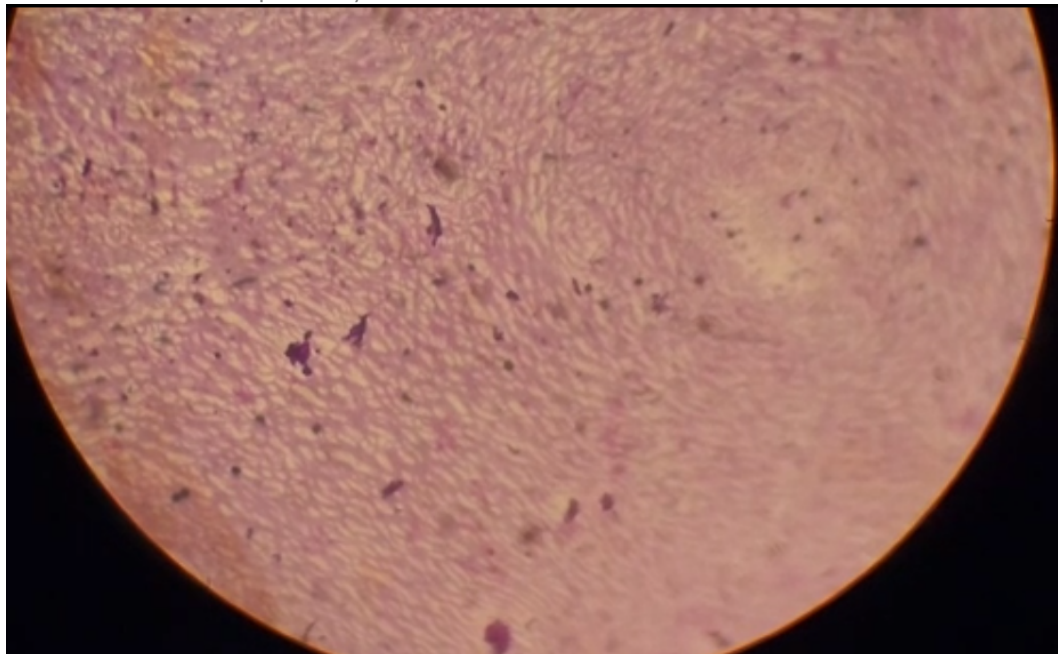


Image shows protein and possible lipid with debris collected from Buddy. There are no nucleated cells to evaluate.



**DATE** 1/11/23 The information and recommendations provided are based on the images presented by the referring veterinarian. No evaluation can be communicated regarding pathology that was not visible in the image/video clips provided.

**INTERPRETED BY** L.D. McGill, DVM, Ph.D., DACVP Thank you for this referral. If the clinical or image interpretation does not parallel your findings or if I can be of any further assistance, please contact me.

L.D. McGill, DVM,  
Ph.D., DACVP

**L.D. McGill, DVM, Ph.D., DACVP**  
8288 Top of the World Drive  
Cottonwood Heights, UT 84121  
ldmcgill.vetpath@gmail.com  
cell: 801-865-1220

**PATIENT**

Buddy Claire

**SPECIES**

Canine

**BREED**

Cross breed

**SEX**

Male

**AGE**

9y

**WEIGHT**

14.1kg

**HOSPITAL NAME**

City veterinary clinic,  
Abu Dhabi, Khalifa City

**REFERRING VET**

Dr. Inam ul haq DVM  
MRCVS

**INVOICE NUMBER**

40637